- If you are viewing this course as a recorded course after the live webinar, you can use the scroll bar at the bottom of the player window to pause and navigate the course.

- This handout is for reference only. Non-essential images have been removed for your convenience. Any links included in the handout are current at the time of the live webinar, but are subject to change and may not be current at a later date.

CONTINUED

Technical issues with the Recording?

- Clear browser cache using these instructions
- Switch to another browser
- Use a hardwired Internet connection
- Restart your computer/device

Still having issues?

- Call 866-782-6258 (M-F, 8 AM-8 PM ET)
- Email customerservice@PhysicalTherapy.com

ROTATOR CUFF LESIONS

Conservative & Post-Operative Management

David Nolan, PT, DPT, MS, OCS, SCS, CSCS

Learner Outcomes

After this course, participants will be able to:

- List at least three predisposing factors related to rotator cuff pathology.
- Identify at least two appropriate rehabilitation interventions for each stage of healing following rotator cuff surgical interventions.
- Develop an evidence-based therapeutic plan of care targeting rotator cuff and scapular region musculature.

Biomechanics

- Scapulohumeral rhythm
  - 2° of GH motion for every 1° of ST motion
  - 180° shoulder elevation
    - 120° humeral elevation
    - 60° scapular rotation

Force Couples

- Deltoid – Rotator Cuff Force Couple
  - Unopposed deltoid = superior migration

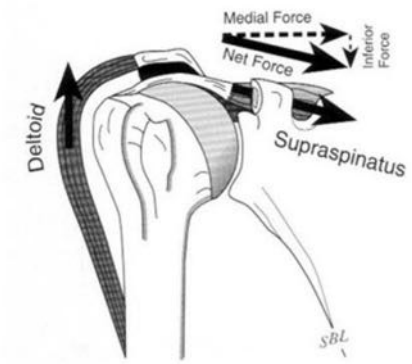

Force Couples

- Anterior-Posterior Rotator Cuff Force Couple
  - Anterior: Subscapularis
  - Posterior: Infraspinatus & Teres Minor

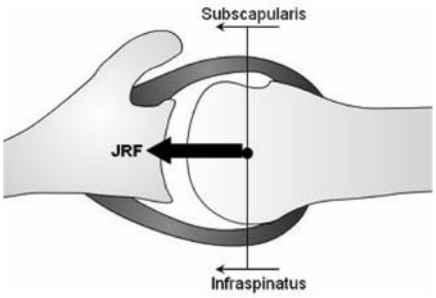

Force Couples

- Upper Trapezius-Serratus Anterior Force Couple
  - Shoulder elevation
  - Upward rotation of scapula
  - Functions
    1. Optimal position of glenoid
    2. Deltoid length-tension
    3. Prevents impingement
    4. Stable base to recruit scapular musculature

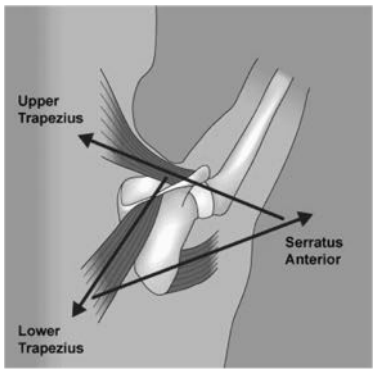

Rotator Cuff

- Provides dynamic stabilization by compressing humeral head into glenoid

Rotator Cuff

- RC muscles blend with capsule & create dynamic ligament tension

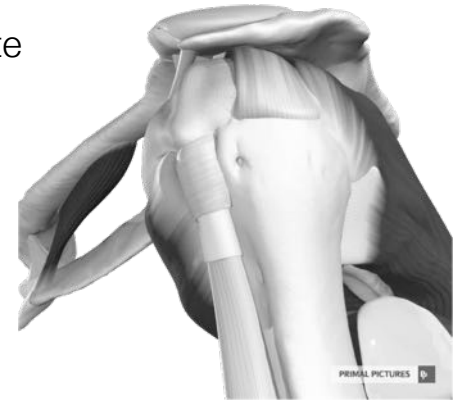

Rotator Cuff Lesions

- Wide spectrum of severity
  - Mild impingement → Full thickness tear
- Progressive failure

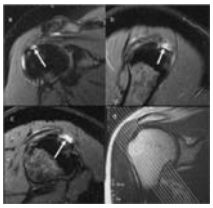

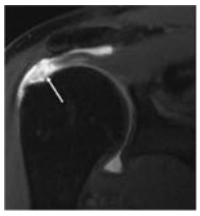

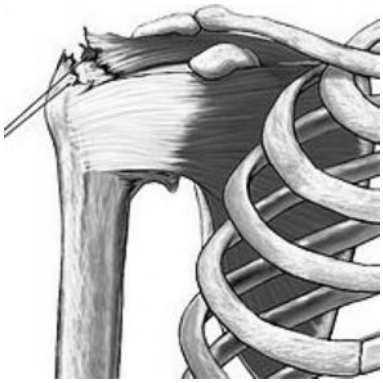

Progressive Process

- Tendonitis
  - Inflammation of the tendon
  - Most often tendon sheath
- Bursitis
  - Inflammation of the subacromial bursa
- Tendonosis
  - Intrasubstance degeneration or tearing

Subacromial Impingement

- Subacromial Space
  - 11mm @ 0°
  - 5.7mm @ 90°
  - Tendons of rotator cuff
  - LHB tendon
  - Subacromial bursa
  - Superior capsule

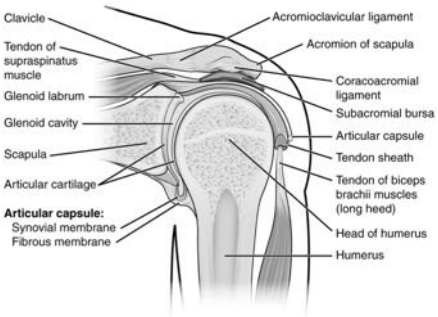

Etiology

- Humeral head depressor weakness / fatigue
- GH instability
- Posterior capsule tightness
- Scapular muscle weakness / Dyskinesia
- Subacromial crowding

Pathology

Inflammation
↓
Tendinitis
↓
Fibrotic scar tissue / tendinosis
↓
Bone Spur
↓
Partial thickness tear
↓
Full thickness tear

Mechanism of Injury

- Acute is rare
- Chronic
  - Repetitive microtrauma
  - Throwing sports
  - Vocational demands

Patient Presentation

- Pain & decreased ROM
- Painful Arc 60° - 120°
- Muscle dysfunction
- Tendon & bursal thickening

Neer Classification

- Stage I
  - Edema and hemorrhage
  - <25 y/o
  - Tenderness @ greater tuberosity & anterior acromion
  - Reversible pathology
  - Treatment = PT

Neer Classification

- Stage II
  - Fibrosis of capsule and bursa
  - Tendinitis of rotator cuff
  - 25-40 y/o
  - Loss of motion evident
  - Recurrent pain with increased activity
  - Treatment = PT & possibly surgery
    - Sub-acromial decompression

Neer Classification

- Stage III
  - Tendinosis / cuff failure
  - Bone spurs & tendon rupture
  - >40 y/o
  - Limited AROM
  - Atrophy of posterior RC
  - Progressive disability
  - Treatment = surgery
    - Sub-acromial decompression & RC repair

Predisposing Factors

- AC joint
  - Degenerative spurs
- Bursa
  - Chronic Thickening
- Capsule / Ligaments
  - Hypermobility
  - Hypomobility

Predisposing Factors

- Scapula
  - Abnormal position / rhythm
    - Winging
    - Anterior tilt

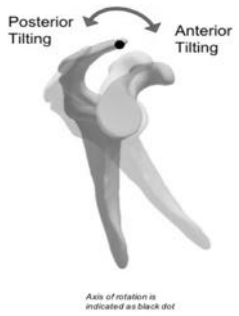

Predisposing Factors

- Acromion
  - Degenerative spurs
  - Malunion / Fracture
  - Shape
    - Type I: Flat
    - Type II: Curved
    - Type III: Hooked

Predisposing Factors

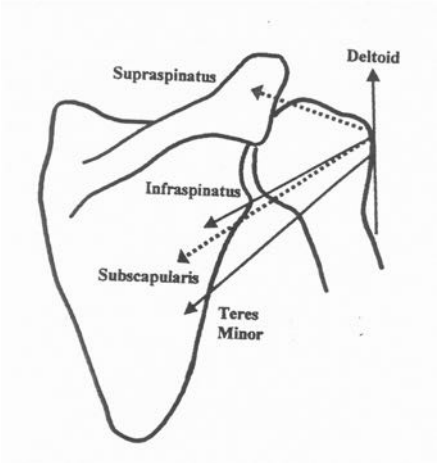

- Rotator Cuff
  - Thickening / Scarring
  - Posterior cuff weakness
  - Deltoid allowed to fire unopposed resulting in superior migration
  - Hypovascular zone?
    - Blood flow decreases with age

Primary Impingement

- Characteristics
  - Hypomobile
  - > 40 yo
  - Etiology
    - Disruption of normal mechanics

Primary Impingement

- Treatment
  - Decrease pain / inflammation
  - Normalize motion
    - Capsular tightness
      - Inferior and posterior
    - Soft tissue adaptive changes
      - Pectoralis minor

Primary Impingement

- Treatment
  - Improve dynamic stability / endurance
    - Posterior cuff
    - Scapular muscles
  - Postural correction
  - Patient education / activity modification

Secondary Impingement

- Characteristics
  - Hypermobility of static stabilizers
  - Overuse leads to loss of dynamic stability provided by rotator cuff
  - 15 – 40 yo

Secondary Impingement

Static Stabilizers stretched

↓

Increased GH translation

↓

RC fatigues

↓

Overuse tendinitis

↓

Tendon fibers fail

↓

RC unable to control HOH during elevation

↓

Superior migration occurs

↓

Muscle dysfunction leads to decreased scapular rotation

↓

Elevation limited by acromion

↓

Impingement syndrome is secondary/resulting pathology

Superior Migration

Secondary Impingement

- Treatment
  - Cuff strengthening
    - Focus posterior
  - Scapular stabilization
    - Retraction
    - Protraction
    - Depression
  - Neuromuscular influences
  - Avoid repetitive microtrauma

Impingement

- Primary vs Secondary
  - Jobe Subluxation / Relocation
    - Primary: No change in symptoms
    - Secondary: Decreased symptoms with ↑ ER

Internal Impingement

- Mechanism
  - Abduction and ER (late cocking phase)
  - Normal shoulder translates posterior
    - Overhead throwing athletes have excessive anterior translation and GH ER
  - Compressive force between greater tuberosity and posterior/superior labrum
  - Undersurface of supraspinatus and infraspinatus implicated

Internal Impingement

- Presentation
  - Pain with excessive ER at 90° Abd
  - Symptoms with overhead activities
  - History of recurrent symptoms
  - Loss of control and velocity

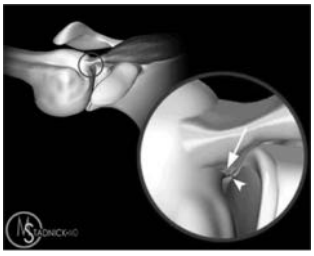

Internal Impingement

- Exam
  - Posterior pain on palpation
    - Infraspinatus tendon
  - Anterior capsule laxity
  - Posterior shoulder tightness (p=.03)
    - Myers et al. *AJSM* 2006
  - Normal ROM
    - ↑ ER and ↓ IR
    - GIRD (p=.03)
      - Myers et al. *AJSM* 2006
  - Weak external rotators
  - Weak scapular muscles
  - (+) Jobe Subluxation/relocation

Internal Impingement

- Treatment
  - Decrease pain / inflammation
    - Avoid irritating motions/activities
  - Dynamic stability of RC
    - Rhythmic stabilization
    - Closed chain drills
  - Scapular muscle training
    - Emphasize retraction & depression
  - Neuromuscular training
    - Perturbation
  - Proper throwing mechanics

Special Testing of the Shoulder Complex

SPECIAL TESTING

Sensitivity

Percentage of patients *with* a particular pathology / diagnosis that are correctly identified by a (+) test.

SnNout: High sensitivity tests with (-) results help rule out a disorder

Specificity

Percentage of patients *without* a particular pathology / diagnosis that are correctly identified by a (-) test.

SpPin: High specificity tests with (+) results help rule in a disorder

SPECIAL TESTING

Positive Likelihood Ratio (LR+)

Shift in probability that favors the *existence* of the disorder

Negative Likelihood Ratio (LR-)

Shift in probability that favors the *absence* of the disorder

LIKELIHOOD RATIOS

LR +	Explanation	LR -
1 to 2	Alters posttest probability of a diagnosis to a minimal degree	.5 to 1
2 to 5	Alters posttest probability of a diagnosis to a small degree	.2 to .5
5 to 10	Alters posttest probability of a diagnosis to a moderate degree	.1 to .2
>10	Alters posttest probability of a diagnosis significantly and almost conclusively	< .1

Impingement Syndrome &
Rotator Cuff Tests

IMPINGEMENT TESTING

- Speed's Test
  - SLAP (Deep)
  - LHB (Anterior)
  - Calis et al (SAI)
    - Sensitivity = 69%
    - Specificity = 56%
    - (+) LR = 1.57 (minimal)
    - (-) LR = .55 (minimal)

IMPINGEMENT TESTING

- Yergason's
  - LHB & THL
  - Calis et al. *Ann Rheum Dis* 2000
    - Sensitivity = 37%
    - Specificity = 86%
    - (+) LR = 2.7 (small)
    - (-) LR = .73 (minimal)

IMPINGEMENT TESTING

- Neer Test
  - Supraspinatus & LHBT
  - MacDonald et al. *JSES* 2000
    - Sensitivity = 75%
    - Specificity = 48%
    - (+) LR = 1.44 (minimal)
    - (-) LR = .52 (minimal)
  - Bak et al. *AJSM* 1997
    - Sensitivity = 39%
    - Specificity = 100%
    - (+) LR = NA
    - (-) LR = .61 (minimal)
  - Calis et al. *Ann Rheum Dis* 2000
    - Sensitivity = 89%
    - Specificity = 31%
    - (+) LR = 1.29 (minimal)
    - (-) LR = .35 (small)

IMPINGEMENT TESTING

- Hawkins-Kennedy
  - Supraspinatus
  - MacDonald et al. *JSES* 2000
    - Sensitivity = 92%
    - Specificity = 44%
    - (+) LR = 1.64 (minimal)
    - (-) LR = .18 (moderate)
  - Bak et al. *AJSM* 1997
    - Sensitivity = 80%
    - Specificity = 76%
    - (+) LR = 3.33 (small)
    - (-) LR = .26 (small)

IMPINGEMENT TESTING

- Hawkins-Kennedy
  - Supraspinatus
  - Rupp et al. *Int J Sports Med*. 1995
    - Sensitivity = 78%
    - Specificity = 100%
    - (+) LR = NA
    - (-) LR = .21 (small)
  - Calis et al. *Ann Rheum Dis* 2000
    - Sensitivity = 92%
    - Specificity = 25%
    - (+) LR = 1.23 (minimal)
    - (-) LR = .32 (small)

IMPINGEMENT TESTING

- Supraspinatus Test / Jobe-Yocum

- Holtby et al: 3 groups
  - (1) Supraspinatus tendinitis partial thickness tear
  - (2) Full thickness tear
  - (3) Large to massive tear
  - Sensitivity = 62%, 41%, 88%
  - Specificity = 54%, 70%, 70%

IMPINGEMENT TESTING

- Internal Rotation Resistance Strength Test
  - Compare IR and ER strength
  - (+) IRRST = ER > IR
    - (+) IRRST: intra-articular
      - ER stronger
    - (-) IRRST: outlet impingement
      - ER weaker
  - Zaslav et al. *JSES* 2001
    - Sensitivity: 88%
    - Specificity: 96%
    - (+) LR: 22.0 (conclusive)
    - (-) LR: .13 (moderate)

ROTATOR CUFF INTEGRITY

- Lag Signs
  - ERLS
    - Infraspinatus
    - Supraspinatus
  - Hertel et al
    - Sensitivity = 70%
    - Specificity = 100%
    - (+) LR = NA
    - (-) LR = .30 (small)

ROTATOR CUFF INTEGRITY

- Lag Signs
  - 90/90 lag sign
    - Infraspinatus
    - Supraspinatus
  - Hertel et al
    - Sensitivity = 36%
    - Specificity = 100%

ROTATOR CUFF INTEGRITY

- Lift-Off Test
  - Subscapularis
  - Gerber C & Krushnell RJ JBJS (Br) 1991
  - Barth JRH et. al. *Arthroscopy* 2006
    - Sensitivity: 17.6%
    - Specificity: 100%
    - PPV: 100%
    - NPV: 76.7%
  - Tokish JM. at. al. *JSES*. 2003
    - Lower fibers via EMG

ROTATOR CUFF INTEGRITY

- Lag Signs
  - IRLS
    - Subscapularis
  - Hertel et al. *JSES* 1996
    - Sensitivity = 97%
    - Specificity = 96%
    - (+) LR = 24.3 (conclusive)
    - (-) LR = .03 (conclusive)

ROTATOR CUFF INTEGRITY

- Belly Press Test
  - Subscapularis
  - Gerber C et al. *JBJS* (Am) 1996
  - Barth JRH et. al. *Arthroscopy* 2006
    - Sensitivity: 40%
    - Specificity: 97.9%
    - PPV: 88.9%
    - NPV: 79.7%
  - Tokish JM. at. al. *JSES*. 2003
    - Upper fibers via EMG

ROTATOR CUFF INTEGRITY

- Napoleon Test
  - Subscapularis
    - Variation of Belly-Press Test
  - Barth JRH et. al. *Arthroscopy* 2006
    - Sensitivity: 25%
    - Specificity: 97.9%
    - PPV: 83.3%
    - NPV: 75.8%

ROTATOR CUFF INTEGRITY

- Bear-Hug Test
  - Subscapularis
  - Barth JRH et. al. *Arthroscopy* 2006
    - Sensitivity: 60%
    - Specificity: 91.7%
    - PPV: 75%
    - NPV: 84.6%

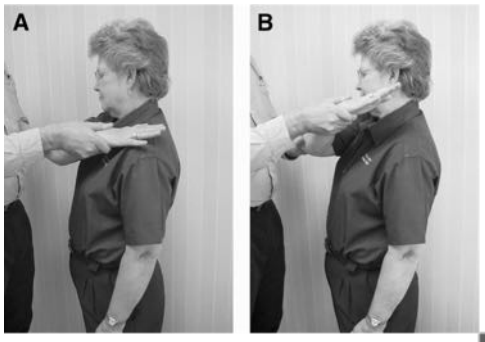

ROTATOR CUFF INTEGRITY

Subscapularis

(+) Bear Hug & Belly Press

Upper 1/3 tears

50% tear needed

(+) Napoleon

75% tear needed

(+) Lift-Off

40% tears missed clinically

Barth JRH et al. *Arthroscopy* 2006

ROTATOR CUFF INTEGRITY

- Hornblower's Sign
  - (+) patient unable to ER
  - Walch et al. *JBJS (Br)* 1998
    - Sensitivity: 100%
    - Specificity: 93%
    - (+) LR: 14.29 (conclusive)
    - (-) LR: 0.0 (conclusive)

ROTATOR CUFF INTEGRITY

- Dropping Sign
  - (+) patient unable to maintain position of ER
  - Walch et al. *JBJS (Br)* 1998
    - Sensitivity: 100%
    - Specificity: 100%
    - (+) LR: NA
    - (-) LR: 0.0 (conclusive)

CONTINUED

SUMMARY

- Impingement Testing
  - Literature is mixed for Neer and Hawkins-Kennedy tests
  - IRRST is helpful differentiating intra-articular dysfunction from outlet impingement
  - Utilizing a diagnostic cluster likely the best approach
- Rotator Cuff Integrity Testing
  - Dropping Sign is sensitive & specific for infraspinatus tears
  - Hornblower sign is sensitive & specific for teres minor tears

CONTINUED

ROTATOR CUFF LESIONS

Surgical Interventions & Rehabilitation

CONTINUED

Influencing Factors

- Bishop J et al. *JSES* 2006
  - Age (healing)
  - Activity level
  - Type of repair
    - Open (deltoid taken down)
    - Mini-Open (deltoid split)
    - Arthroscopic
  - Tissue quality
    - Soft tissue integrity
      - Repair and surrounding tissue
    - Osseous integrity
      - Fixation strength

Influencing Factors

- Size of tear
  - Bishop J et al. *JSES* 2006
  - Small: <1cm
  - Medium: 1-3cm
  - Large: 3-5cm
  - Massive: >5cm

CONTINUED

Influencing Factors

- Location of tear
  - Isolated supraspinatus
  - Supraspinatus and Infraspinatus
  - Subscapularis

CONTINUED

Positive Outcome

Prognostic Factors for Successful Recovery After Arthroscopic Rotator Cuff Repair: A Systematic Literature Review

- Fermont A. et al. *J Orthop Sports Phys Ther*. 2014
  - Demographic Factors
    - Younger age, male gender
  - Clinical Factors
    - Higher BMD, (-) DM, (-) obesity, ↑ pre-op ROM, ↑ sports activity

Positive Outcome

- Fermont A. et al. *J Orthop Sports Phys Ther*. 2014
  - Cuff Integrity
    - Smaller sagittal size, less retraction, less fatty infiltrate, (-) multiple tendon involvement
  - Surgical Procedure
    - (-) concomitant biceps or AC procedures

Surgical Interventions

- Impinging Lesions
  - Arthroscopic Acromioplasty
    - Acromial spur removed
    - Coracoacromial ligament released
    - AC joint osteophytes excised

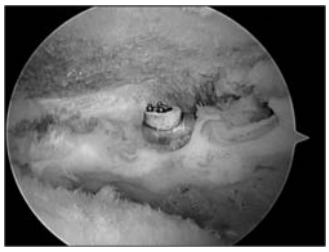

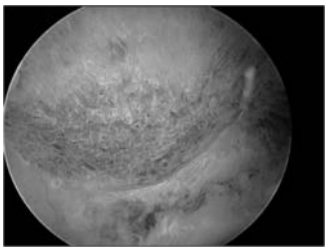

Surgical Interventions

- Full Thickness Rotator Cuff Tear
  - Open repair
    - Pros
      - Exposes all involved anatomy
      - Allows for mobilization of tendons
    - Cons
      - Release of deltoid
      - Hospital stay
      - Longer rehab
      - Unable to examine GH joint and subacromial space
      - Decreases cosmesis

Surgical Interventions

- Full Thickness Rotator Cuff Tear
  - Arthroscopically Assisted Mini-Open Repair
    - Pros
      - Visualization of cuff tear (open)
      - No deltoid release (arthroscopy)
      - Possibly better fixation

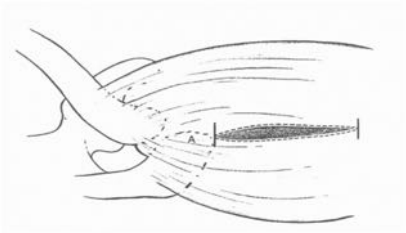

Mini-Open Surgical Technique

- Visualization of Supraspinatus tear

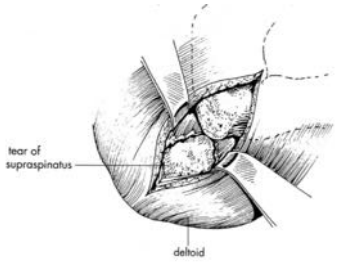

- Retraction from footprint

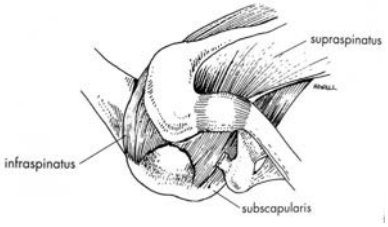

Mini-Open Surgical Technique

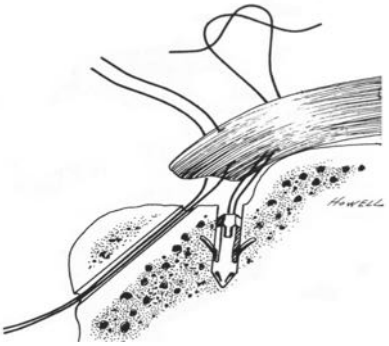

- Sutures through bone tunnel
- Suture Anchors

Mini-Open Surgical Technique

- Tear is brought back to footprint
- Bony notch to improve healing

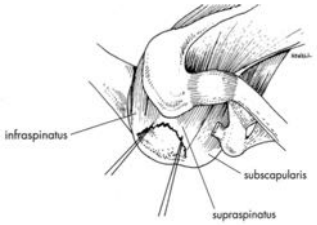

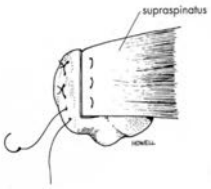

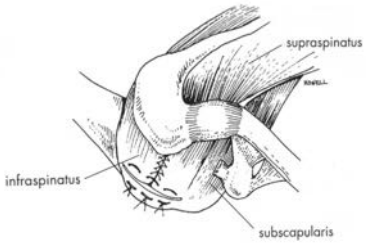

Surgical Interventions

- Full Thickness Rotator Cuff Tear
  - Arthroscopic Rotator Cuff Repair
    - Pros
      - No deltoid release
      - Limited morbidity
      - Accelerated rehab
      - Improved cosmesis
    - Cons
      - Technically demanding

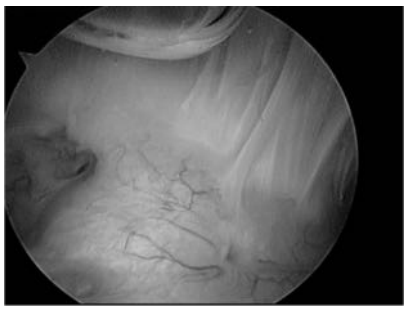

Platelet-Rich Plasma

- Hak A et al. *Sports Health*. 2014
  - RCT: 25 patients (12 PRP; 13 saline)
    - 1 injection intra-op & 1 @ 4-weeks post-op
  - 6-week F/U; No statistical difference in outcomes
    - VAS, EQ-5D, WORC, DASH
- Malavolta EA et al. *Am J Sports Med*. 2018
  - RCT: 51 patients (26 PRP; 25 control)
  - 5 year F/U; No difference in outcomes
    - UCLA, Constant, VAS

Surgical Video

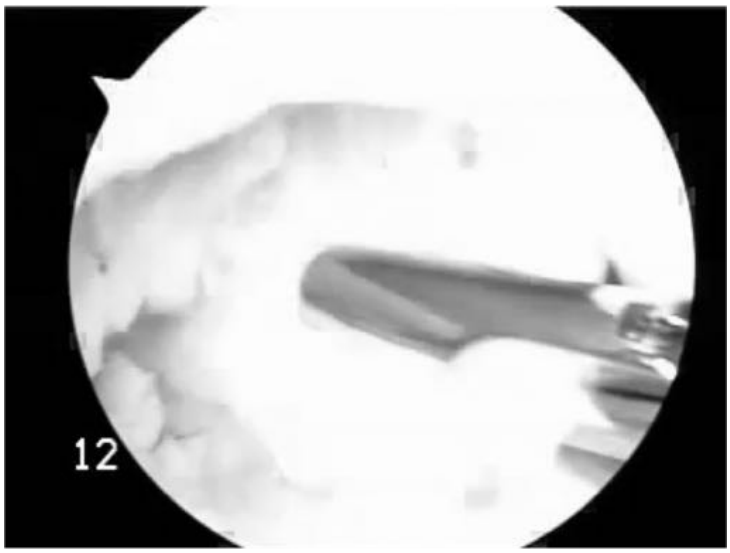

CONTINUED

Failure

- Integrity of Repair
  - 22% had recurrent tears on MRI at 2 Yr F/U
    - Cole BJ et al *JSES* 2007
  - 40% of tendons not healed
    - DeFranco MJ et al. *JSES* 2007
  - 88% (15/17) showed leakage with MR Arthrography
    - Meyer M et al. *JSES* 2012
  - *Anatomic Integrity does not correlate with functional outcomes or patient satisfaction*

CONTINUED

Delayed Mobility ?

Does Slower Rehabilitation After Arthroscopic Rotator Cuff Repair Lead to Long-term Stiffness?

- Parsons BO. et al. *Journal of Shoulder and Elbow Surgery*. 2010 Volume 19, Issue 7 Pages 1034-1039.
  - Sling immobilization for 6 weeks post-op
    - Did not result in long term stiffness (1 yr)
    - May improve rate of tendon healing (less re-tears)

Rehabilitation

A Comparison of Rehabilitation Methods After Arthroscopic Rotator Cuff Repair: A Systematic Review

Yi A et al. Sports Health, 2015

- No significant difference between early versus late mobilization approaches

Post-Operative Rehabilitation

- Phase I (0-6 weeks)
  - Passive exercises
  - Minimize load across repair
- Phase II (6-10 weeks)
  - Active exercises
  - Gradual load repair
- Phase III (10-12 weeks)
  - Resistive exercises
  - Restore force production of cuff
- Phase IV (16-24 weeks)
  - Restore maximum strength, power, endurance

Range of Motion Goals

	Passive Scaption	Passive ER 20° Abd	Passive ER 90° Abd	Active Scaption
POD 1	60°- 90°	0°– 15°	NA	NA
POW 1	60°– 90°	0°– 20°	NA	NA
POW 3	90°– 100°	15°– 30°	NA	NA
POW 6	90°– 120°	20°– 45°	40°– 60°	NA
POW 9	130°– 155°	30°– 60°	50°– 75°	80°– 120°

Rehabilitation

- Phase I (0-6 weeks): Protect Repair
  - Immobilization in Abduction sling
    - Prevent "wringing out"
    - ↓ tension on repair
  - PROM
    - May assist with proper orientation of type 1 collagen
    - Assist with proper tendon gliding
  - "Stretching" should be avoided
  - Establish voluntary muscle control

CONTINUED

Rehabilitation

- Phase I interventions
  - Patient education key
  - Sling 4-6 weeks (per MD)
  - Immediate PROM
    - Elbow wrist and hand (modify with biceps involvement)
    - Achieve staged ROM goals
    - Scapular plane
    - Caution excessive Abd & IR
    - Avoid pulleys
      - EMG shows RC is active (Burkhart SS et al. *Arthroscopy*. 1997)
  - Manual scapular strength
  - Cryotherapy
    - Control post-op pain
    - ↓ swelling & muscle spasm

CONTINUED

Rehabilitation

- Milestones to Progress to Phase II
  - Appropriate healing
    - Compliant with immobilization
    - Compliant with precautions
  - Staged ROM goals on target
    - Scaption (90° – 120°)
    - ER 20° Abd (20° – 45°)
    - ER 45° Abd (40° – 60°)
  - Minimal pain with ROM
    - ≈ 2/10

Rehabilitation

- Phase II (6-12 weeks)
  - D/C Sling
    - Consider pain and compliance
  - Progress to full PROM
  - Initiate self-assisted & AAROM → AROM
    - Focus on good mechanics
  - Strengthening
    - No resisted RC exercise
  - Scapulothoracic focus
    - Dynamic stability
  - Independent with ADLs (Week 12)

Rehabilitation

- Phase II interventions
  - Continue P-A-AAROM
    - Pec minor
  - Continue rhythmic stabilization
    - Middle and lower trapezius
  - Strength (10-12 weeks)
    - Isometrics
    - Scaption with ER (Full Can)
    - Sidelying Abduction to 45°
      - ↑ Supraspinatus with ↓ risk of impingement
    - Avoid painful exercises
  - Initiate low level functional activities

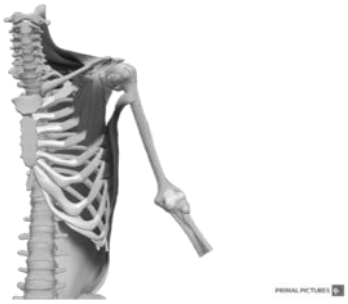

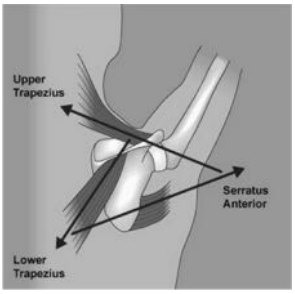

CONTINUED

Rehabilitation

- Milestones to Progress to Phase III
  - Staged AROM achieved
    - 0-2/10 pain
    - Without compensation
  - Strengthening Activities progressing
    - 0-2/10 pain
  - Normal scapular position
    - Static and dynamic

CONTINUED

Rehabilitation

- Phase III (12 - 24 weeks)
  - Goals
    - Full P / AROM
    - Dynamic shoulder stability
    - Shoulder strength & endurance
    - CKC activities
    - Neuromuscular Re-Ed
      - Joint reposition
    - Return to work activities
    - Initiate modified recreational activities

Rehabilitation

- Phase III Interventions
  - Scapular plane initially
  - No compensatory patterns
  - High repetition focus

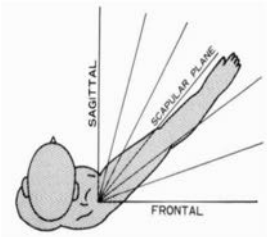

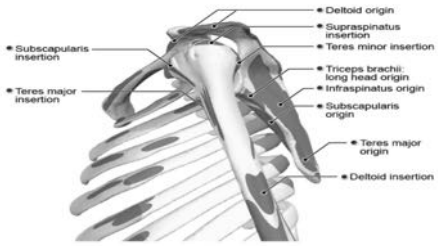

Rehabilitation

- Milestones to Progress to Phase IV
  - Adequate strength & dynamic stability for progression to work / sport activity
  - Normal scapular position
    - Static and dynamic

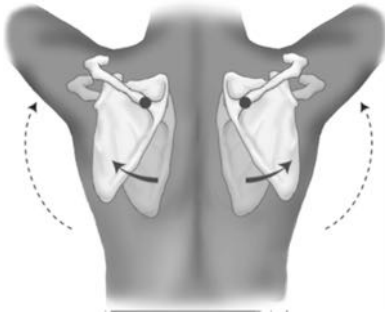

Rehabilitation

- Phase IV
  - Replicate demands of ADL and work activity
  - Plyometric program
  - Initiate interval sport program

Massive Rotator Cuff Tears

- 40% of all RC tears (Greenspoon JA et al. *JSES*. 2015)
  - Atrophy & fatty infiltrate
- Management of irreparable tears
  - Non-Operative
    - Low demand patients; OA over time
  - Partial Repair & Debridement
    - Good results; limited long-term data
  - Reverse TSA
    - Elderly patients with advanced OA
  - Latissimus Dorsi Transfer (Namdari S et al. JBJS Am. 2012)
    - Younger patients with posterosuperior tears
    - High complication rates

Massive Rotator Cuff Tears

- Superior Capsule Reconstruction
  - Mihata T et al. AJSM. 2012
    - Technique
      - Fascia Lata autograft
      - Dermal allograft
    - Prevents superior migration
    - Functioning deltoid & subscapularis

Massive Rotator Cuff Tears

<u>Superior Capsule Reconstruction for Massive Rotator Cuff Tears-Key Considerations for Rehabilitation</u>

- Post-Operative Rehabilitation
  - Pogorzelski J et al. IJSPT. 2017

Phase 1: Maximal Protection

- Goals:
  - Protect repair
  - Minimize pain/inflammation
  - Maintain mobility accessory joints
  - Patient education
- Interventions:
  - Immobilized in abduction sling x6 weeks
  - Cryotherapy
  - AROM cervical spine
  - AROM elbow, wrist, hand out of sling
  - Ball squeezes
  - Scapular retraction/depression

Phase 2: ROM & Endurance

- Goals:
  - Restore ROM
  - ↑ RC endurance
  - Restore scapulohumeral rhythm
  - Initiate *light* ADLs
  - Ween sling
- Interventions:
  - PROM / AROM to tolerance
  - Deltoid activation
  - ER function (dependent on tissue quality)
  - Scapular & GH isometrics

Phase 2: ROM & Endurance

- SL Abduction

- SL H-Abduction

Phase 3: Strength

- Goals:
  - Advanced strength
  - Restore functional ROM
  - Resume higher level functional activities
- Interventions:
  - Progressive resisted ROM
  - Initiate CKC exercises
  - **Normal scapulohumeral rhythm**

Phase 4: Advanced Strength / Return to Activity

- As appropriate
- Interventions:
  - **Endurance**
  - Overhead strength
  - Advanced CKC
  - Plyometrics

Keys to Success

- Establish PROM
- Restore ER strength
- Establish shoulder balance
- Improve scapular position & movement
- Gradually increase loads
- Avoid aggressive activities early on
- Gradual return to functional activities

Therapeutic Exercise Considerations

Shoulder Complex Function

- Goals:
  - Joint compression
  - Dynamic ligament tension
  - Neuromuscular control
  - Scapulothoracic Control
  - Mobility → **Stability** → **Controlled Mobility** → **Skill**

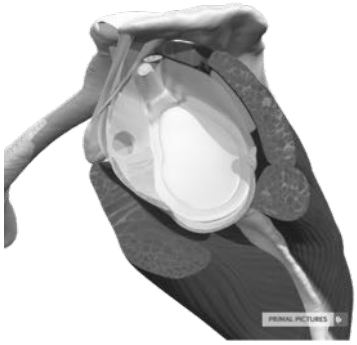

Force Couples

- Deltoid – Rotator Cuff
  - Unopposed deltoid = superior migration

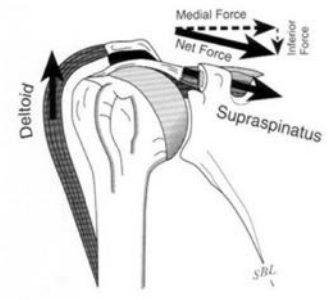

- Anterior-Posterior Rotator Cuff
  - Anterior:
    - Subscapularis
  - Posterior:
    - Infraspinatus & Teres Minor

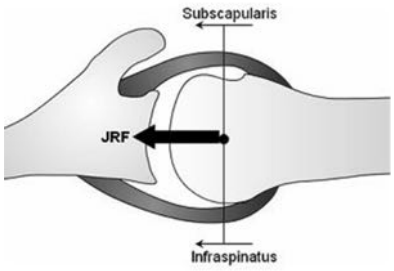

Force Couples

- Upper Trapezius-Serratus Anterior
  - Shoulder elevation
  - Upward rotation of scapula
  - Functions
    - Optimal position of glenoid
    - Deltoid length-tension
    - Prevents impingement
    - Stable base to recruit scapular musculature

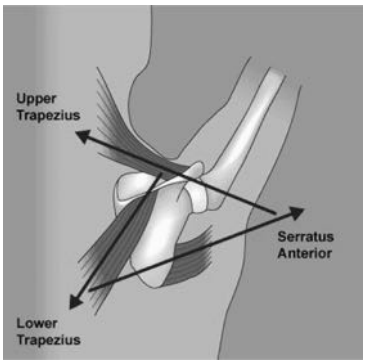

No Cook Books

- Emphasis should be an individualized approach
  - Consider specific deficits and demands
  - Respect the surrounding tissues and stage of healing
    - Control Pain & Inflammation

EMG Considerations

- Surface vs. fine wire EMG
  - "Cross Talk"
- Isometric contractions vs. dynamic movement
- Healthy subjects vs. patients with shoulder pathology
- Subject demographics

Glenohumeral Muscles

- Townsend et al. *AJSM* 1991
  - "Best" exercises
    - Scaption in IR "Empty Can"
      - 74% MVIC Supraspinatus
        - Scaption in ER = 64%
      - 62% MVIC Subscapularis
    - Flexion
      - 67% MVIC Supraspinatus
    - Horizontal Abd with ER
      - 88% MVIC Infraspinatus
      - 74% MVIC Teres Minor
    - Press-up

Empty Can?

- Townsend et al. *AJSM* 1991
  - Highest Anterior Deltoid (72% MVIC) & Middle Deltoid (83% MVIC)
- Flatow EL et al. *AJSM,* 1994
  - May be painful 2°impingement position
  - ↑ superior migration of humeral head
- Kelly et al. *AJSM*, 1996
  - 11 subjects; Non-dominant shoulders
  - Supraspinatus isolation best achieved: Scaption with ER
  - Less deltoid in "full can" position
- Itoi et al. *AJSM*, 1999
  - EMG activity similar between thumb up and down positions
  - Thumb up was more comfortable
- Thigpen et al. *AJSM*, 2006
  - ↑ Anterior tipping & IR of scapula in "Empty Can" position = ↓ Subacromial space
- Reinold et al. *J Athl Train*, 2007
  - Less deltoid with full can
    - 84% full can; 124% empty can

Force Couples

- Deltoid – Rotator Cuff Force Couple
  - Unopposed deltoid = superior migration
  - Yasojima T et al. *Med Sci Sports Exerc*. 2008
    - Full Can at lower loads = best supraspinatus to deltoid rat
  - Bitter NL et al. *J Shoulder Elbow Surg*. 2007
    - Isometric ER @10-40% MVIC maximized infraspinatus and minimized deltoid

Rotator Cuff

Scapulothoracic and Scapulohumeral Exercises: A Narrative Review of Electromyographic Studies

- Cricchio M & Frazer C. *J Hand Ther*. 2011
  - Reviewed 22 EMG studies; Highest activation

Exercise	Primary Muscle
Isometric ER	Infraspinatus
Sidelying ER	Infraspinatus, Teres Minor
Full Can	Supraspinatus
Prone H-Abd @100°full ER	Supraspinatus
Push-Up Plus	Subscapularis
Diagonal D2 Extension	Subscapularis

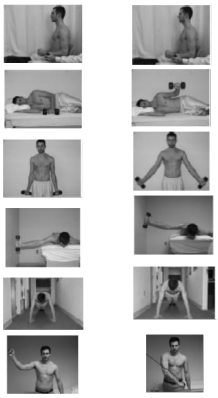

External Rotation

- Reinold MM et al. *JOSPT* 2004
  - Sidelying ER = Greatest EMG
    - Infraspinatus: 62% MVIC
    - Teres Minor: 67% MVIC
  - Towel Roll
    - ↑ infraspinatus muscle activity: 10% ↑ in EMG
    - Improved form: keep arm at side
  - ER at 90°Abduction
    - Functional position for overhead athletes/workers
    - Caution: ↑ strain on capsule in 90°- 90° position
    - Avoid in early rehab

External Rotation

- Manual Therapy
  - Manual resistance
  - Incorporate concentric & eccentric contractions

Subscapularis

- Decker et al. *AJSM*, 2003
  - 15 healthy subjects
  - Upper and lower fibers of subscapularis act independently
  - Greatest subscapularis activity:
    - Push-up plus
    - Diagonal exercise (tennis forehand)
  - IR at 0° not ideal due to co-contraction of
    - Anterior deltoid
    - Pectoralis major
    - Latissimus dorsi

Scapular Dysfunction

The Association of Scapular Kinematics and Glenohumeral Joint Pathologies

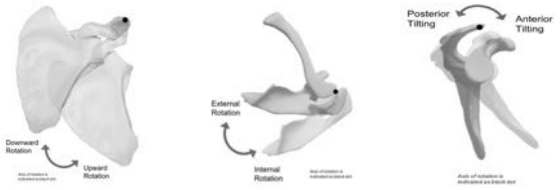

Ludewig PM & Reynolds JF. *J Orthop Sports Phys Ther*. 2009

Impairment / Biomechanical Cause	Faulty Scapular Pattern
↓ Serratus Anterior strength	↓ Scapular upward rotation & posterior tilt
↓ Pec Minor length	↑ Scapular IR & anterior tilt ↓ Scapular upward rotation & posterior tilt
↑ Thoracic kyphosis / flexed posture	↑ Scapular IR & anterior tilt ↓ Scapular upward rotation & posterior tilt
↓ Posterior GHJ Soft tissue length	↑ Scapular anterior tilt

Mobility

- Pec Minor
  - Muscle tightness may lead to reciprocal inhibition
    - Weakness of antagonist
  - Borstad JD et al. *JSES* 2006
    - Doorway stretch
      - (+ 2.24 cm)
    - Supine manual stretch
      - (+ 1.69 cm)
    - Seated manual stretch
      - (+ 0.77 cm)
  - Muraki T et al. Phys Ther. 2009
    - Shoulder retraction in 30°fwd flex
- Thoracic Spine

Scapular Stabilizers

- Moseley JB et al. *Am J Sports Med*. 1992
  - "Best" exercises
    - Scaption
    - Rowing
    - Push Up Plus
    - Press Up

Scapular Stabilizers

Scapulothoracic and Scapulohumeral Exercises: A Narrative Review of Electromyographic Studies

- Cricchio M & Frazer C. *J Hand Ther*. 2011
  - Reviewed 22 EMG studies; Highest activation

Exercise	Primary Muscle
Prone Extension	Middle Trapezius
Prone T	Middle & Lower Trapezius
Prone Y	Middle & Lower Trapezius
Inferior Glide	Serratus Anterior, Lower Trapezius
Isometric Low Row	Serratus Anterior, Lower Trapezius



Scapular Stabilizers

Scapulothoracic and Scapulohumeral Exercises: A Narrative Review of Electromyographic Studies

- Cricchio M & Frazer C. *J Hand Ther*. 2011
  - Reviewed 22 EMG studies; Highest activation

Exercise	Primary Muscle
Lawnmower	Serratus Anterior, Lower Trapezius
Push-Up Plus	Serratus Anterior, Lower Trapezius
Wall Slide	Serratus Anterior
Dynamic Hug	Serratus Anterior

Trapezius

- Ekstrom RA. et. al. *JOSPT* 2003
  - Surface EMG 30 healthy subjects
  - Upper Trapezius
    - Unilateral shrug (%MVIC 119 ± 23)
  - Middle Trapezius
    - Prone elevation (%MVIC 101 ± 32)
    - Prone Horizontal Ext (%MVIC 87 ± 20)
  - Lower Trapezius
    - Prone Elevation (%MVIC 97 ± 16)

Trapezius

- McCabe RA. et. al. *NAJSPT* 2007
  - Lower Trapezius below 90°
    - Seated press up
    - Unilateral scapular retraction

Exercise	UT %MVIC	MT % MVIC	LT % MVIC	SA % MVIC
Press Up	27	32	56	44
Scap Retraction	62	50	51	26
B Shoulder ER	17	37	40	29
Scap Depression	20	19	21	41

Trapezius

- Cools AM. et al. *AJSM* 2007
  - 45 healthy subjects
    - Mean age = 20.7 ± 1.7
    - Surface EMG
      - Upper, Middle, Lower trapezius
      - Serratus Anterior
  - Examined 12 exercises
  - UT/LT
    - SL flexion, SL ER, Prone H-Abd in ER
  - UT/MT
    - SL flexion, SL ER, Prone Ext

Trapezius

- De Mey K. et al. *AJSM* 2012
  - OH Athletes with Mild Impingement; 6-week exercise program
  - Prone H-Abd with ER, Sidelying Flexion, Sidelying ER, Prone Extension
  - SPAD I scores improved
    - 29.86 ± 17.03 to 11.7 ± 13.78 (P<.001)
    - Improved pain and function
  - Increased MVIC of trapezius muscles
  - Earlier activation of LT compared to UT and MT (P<.001)
  - Earlier activation of SA compared to UT & MT (P<.001) and LT (P<.046)

Early Rehabilitation

- Kibler et al. *AJSM* 2008
  - 39 subjects
  - Mean age of 29.62 yrs
  - Asymptomatic
    - 9 male / 9 female
  - Symptomatic
    - 13 male / 8 female
    - Dx of impingement (9), labral pathology (5) or RC tendinopathy (7)
    - Demonstrated scapular dyskinesis
  - Surface EMG
    - Serratus Anterior
    - Upper and Lower Trapezius
    - Anterior and Posterior Deltoid

Early Rehabilitation

- Kibler et al. *AJSM* 2008
  - 4 Exercises
    - Inferior Glide
    - Low Row
    - Lawnmower
    - Robbery



Early Rehabilitation

- Kibler et al. *AJSM* 2008
  - No difference among groups
  - Serratus Anterior activated 1st in inferior glide and low row
  - Serratus Anterior activated last in lawnmower and robbery
  - Key is position of scapular retraction



Serratus Anterior

Ludewig PM et. al. *AJSM* 2004

- Healthy & mild dysfunction groups
- Surface EMG of SA and UT
- Low UT/SA ratio
  - Standard Push-Up Plus was optimal
- Wall Push-Up Plus
  - Highest UT activation of all positions tested

Serratus Anterior

<u>Serratus Anterior or Pectoralis Minor: Which Muscle Has the Upper Hand During Protraction Exercises</u>?

- Castelein R t al. *Man Ther*. 2016
  - SA Punch with pulley resistance
  - Max Serratus Anterior with Min Pec Minor

Serratus Anterior

- Ekstrom RA. et. al. *JOSPT* 2003
  - Surface EMG 30 healthy subjects
  - Serratus Anterior
    - Diagonal exercise
      - Flexion, horiz flexion, ER
      - %MVIC 100 ±
    - Scaption above 120°
      - %MVIC 96 ± 24



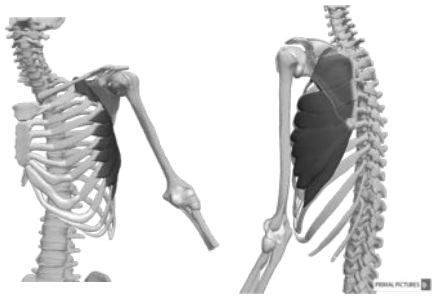

Serratus Anterior

- Hardwick et al. JOSPT, 2006
  - 20 healthy subjects performed:
    - Wall Slide
    - Push-Up (+)
    - Scaption
  - Serratus Anterior activity was similar for all 3 exercises
  - Wall slide activates Serratus Anterior above 90° of elevation

Serratus Anterior

- Park S-y. et al. *Manual Therapy* 2013
  - 16 healthy, active volunteers
  - Surface EMG
    - Lower SA
    - Middle SA
    - Upper Trapezius
  - Scapula protraction key

Muscle	Elevation	Diagonal Elevation	Dynamic Hug	Dynamic Hug (+)	Push-Up (+)
MSA	48.2	63.6	45	85.1	54.6
ISA	41.6	62.7	35	67.7	65.6
UT	49	36.3	7.7	4.3	3.6

Scapular Musculature

Superficial and Deep Scapulothoracic Muscle Electromyographic Activity During Elevation Exercises in the Scapular Plane

Castelein B et al. *JOSPT* 2016

- 21 Healthy subjects
- Fine wire and surface EMG
- Weighted and non-weighted
  - Elevation in scapular plane
  - Towel wall slide
  - Elevation with ER & Tband

- Upper Trap: ↑ Activation with Scaption
- Middle & Lower Trap: ↑ Activation with Elevation & ER
- Serratus Anterior: ↑ Activation with all 3 exercises
- Pec Minor: ↑ Activation with Wall Slide

Castelein B et al. *JOSPT* 2016

A Systematic Review of the Exercises That Produce Optimal Muscle Ratios of the Scapula Stabilizers in Normal Shoulders

- Schory A, et al. *IJSPT* 2016
  - Upper trapezius had the GREATEST activity during standing exercises
    - Highest during 60°-120°
  - Upper trapezius had the LEAST activity during exercises in prone, side-lying and supine

Summary

Optimal Exercise Prescription is Multi-Factorial

- Individualized to address deficits of dynamic stability
- Specific demands of the patient
- Stage of healing
- Pain level
- Concomitant injury

continued

Thank You