- If you are viewing this course as a recorded course after the live webinar, you can use the scroll bar at the bottom of the player window to pause and navigate the course.

- This handout is for reference only. Non-essential images have been removed for your convenience. Any links included in the handout are current at the time of the live webinar, but are subject to change and may not be current at a later date.

CONTINUED

Technical issues with the Recording?

- Clear browser cache using these instructions
- Switch to another browser
- Use a hardwired Internet connection
- Restart your computer/device

Still having issues?

- Call 866-782-6258 (M-F, 8 AM-8 PM ET)
- Email customerservice@PhysicalTherapy.com

CONTINUED

Hot Topics in Pediatrics

Guest Editor: Lisa Kenyon, PT, DPT, PhD, PCS

11/5: Evidence Based Physical Therapy Management of Idiopathic Toe Walking
Sally P. LeCras, PT, DPT, PCS
11/6: What Are We Waiting For? The Power of Early Mobility
Lisa Kenyon, PT, DPT, PhD, PCS
11/7: Meeting the Sensory Needs of Children with Autism Spectrum Disorder(ASD): A Primer for Therapy Professionals
Melissa Tovin, PT, MA, PhD, PCS, CEEAA
11/8: Keys to Physical Literacy and Fundamental Movement Skills for Children Who Use Wheelchairs: Consideration for Adapted Sport and Inclusive Physical Education
Krista Best, PhD
11/9: Clinical Application of the Congenital Muscular Torticollis Clinical Practice Guideline
Micah Huegel, PT, DPT

CONTINUED

Clinical Application of the Congenital Muscular Torticollis Clinical Practice Guideline

By Micah Huegel

CONTINUED

Learning Outcomes

At the completion of this lecture, attendees will be able to:

- Practically apply identify at least three clinical practice guideline for congenital muscular torticollis to patients within a variety of settings.
- List at least three appropriate interventions in the management of congenital muscular torticollis.
- Identify the discharge criteria to determine when it is appropriate to discontinue care for an individual with congenital muscular torticollis.

CONTINUED

Purpose of CPGs

- Assists with identification and management of children with issues of the following
  - Participation, activity, body function and structures
  - Related to cardiorespiratory, musculoskeletal, developmental, and neuromuscular conditions
- Provides who, what, how, and when to treat and/or refer

General Overview[1]

- Seventeen Action Statements
- Four categories
  1. Education, identification, and referral of infants with congenital muscular torticollis (CMT)
  2. Physical Therapy Examination of infants with CMT
  3. Physical Therapy Intervention for infants with CMT
  4. Discharge & Follow-Up of infants with CMT

Torticollis Overview and Prevalence

- Synonyms: Fibromatosis colli, wry neck, or twisted neck
- Prevalence: 3.9% to 16%[2,3]
  - More common in males and in utero exposure to opioids[4]
  - Other risk factors: Longer babies, breech presentation, and/or forceps during delivery

CONTINUED

Types of Torticollis[1]

- Three types
  - Postural: Infant's postural preference without PROM restrictions. Mildest presentation
  - Muscular: SCM tightness and PROM restrictions
  - SCM Mass: Fibrotic thickening of SCM with PROM restrictions. Most severe form

CONTINUED

Sternocleidomastoid

- Primary muscle involved
  - Ipsilateral head tilt
  - Contralateral rotation
- Can occur in utero or after birth

CONTINUED

Torticollis Overview and Prevalence

- Key indicators for duration of care: Severity and age of initial diagnosis
  - <1 month: 98% normal range in 1.5 months[5]
  - 3-6 months with a mass have longest episodes of conservative treatment[6]

Referral Age	Length of Care
<1 month	~1.5 months
>1 month	Up to 6 months
6+ months	9-10 months

CONTINUED

Cranial Asymmetries

- Newborn screens for head shape
  - 1 week and 1 month
  - No specific recommendations after 2 months
- SHOULD be getting a referral at 2 months to physical therapy[7]

CONTINUED

Associated Diagnoses[1]

- Hip dysplasia
- Brachial plexus injury
- Distal extremity deformities
- Early or persistent developmental delay
- Facial asymmetry
- TMJ dysfunction

CONTINUED

Case Report

- 2 month old presents to an outpatient clinic for a PT examination related to concerns regarding a diagnosis of torticollis.
- Details will emerge as we discuss each Action Statement

continued

Education, Identification and Referral of Infants with CMT

1. Educate expectant parents and parents of newborns on positioning
2. Identify newborns at risk for CMT
3. Refer Infants with asymmetries to physician and physical therapist
4. Document infant history
5. Screen Infants
6. Refer infants from PT to physician if red flags are identified
7. Request images and reports

continued

AS 1: Educate Expectant Parents and Parents of Newborns on Positioning[1]

- Education falls upon physicians, nurse midwives, prenatal educators, nurse practitioners, and/or physical therapists
  - Symmetrical positioning
  - Supervised tummy time 3+/day, full active movement
- First 2 days of birth
- Shorter episodes of care

AS 1: Educate Expectant Parents and Parents of Newborns on Positioning

- Current education[8]
  - 90% learn about supine sleeping
  - 27% learn about prone play
  - 2 months later: 8% tummy time during awake time
    - 70% of them only 1-2x per day
- "Prone for play, back to sleep"[1]

AS 2: Assess Newborn Infants for Asymmetries/CMT[1]

- Any health professional or family member
  - Assess neck or cranial/facial asymmetries within first 2 days
    - Chin to/past shoulder for rotation
    - Ear to shoulder for lateral flexion
  - PROM rotation, lateral flexion and visual observation
- Easily perform PROM assessment in first 3 days of life

AS 2: Assess Newborn Infants for Asymmetries/CMT

- Higher risk[1]
  - Longer body length
  - Primiparity
  - Birth trauma
  - Facial asymmetry
  - Plagiocephaly
  - Neonatal abstinence syndrome
    - Postnatal medication[9]
- Early detection = Shorter POC[10]

Case AS 2: Assess Newborn Infants for Asymmetries/CMT

- Age at eval: 2 months and ~10 days
- Physician referral following 2 month Well Child visit
- Mother noticed decreased R rot ~2 weeks after birth

continued

AS 3: Refer Infants with Asymmetries/CMT to Physician and PT[1]

- Reasons to refer:
  - Positional preference
  - Reduced cervical ROM
  - SCM masses
  - Facial asymmetry
  - Plagiocephaly

continued

AS 3: Refer Infants with Asymmetries/CMT to Physician and PT

- 1 month check-up
  - May not be prevalent immediately after birth
- First 2 months of life = greater tolerance to stretch
  - Optimal HEP compliance
- Initiation correlation with excellent outcomes
  - 1 month: 99%; 1.5 months
  - 1-3 months: 89%; 5.9 months
  - 3-6 months: 62%; 7.2 months
  - 6-12 months: 19%; 8.9 months[5]

continued

AS 3: Refer Infants with Asymmetries/CMT to Physician and PT

- Therapy compared to parent-only stretching
  - Reduced overall intervention time[11]
- Able to provide instructions for extensive HEP and tummy time promotion

continued

Case AS 3: Refer Infants with Asymmetries to Physician and PT

- Mother initially noticed the preference and brought it up at the well child visit
- Referral sent to Mary Free Bed
- Evaluation when patient was 2 month and 10 days old

CONTINUED

AS 4: Document Infant History

- Obtain general medical and developmental history via 9 specific health history factors

1. Chronological Age & corrected age
2. Age of onset
3. Pregnancy history
   - Sense of baby being "stuck"[12]
4. Delivery (cephalic or breech)
   - Infant size (low or large/long)[13]
5. Use of forceps or suction during delivery

CONTINUED

AS 4: Document Infant History

6. Head posture/preference
   - Asymmetries
7. Family history of torticollis
8. Other known or suspected medical conditions
9. Developmental milestones

CONTINUED

Case AS 4: Document Infant History

- Age at initial visit: 2 months and 10 days
- Age of onset: 2 weeks
- Pregnancy history: Full term without complication
  - Child was blue and limp upon delivery but 5 minute APGAR was normal
- Delivery (cephalic or breech): Cephalic
- Use of forceps or suction during delivery: None

CONTINUED

Case AS 4: Document Infant History

- Head posture/preference: Prefers left rotation and right tilt
- Family history of torticollis: None
- Other known or suspected medical conditions: R ventricular hypertrophy that has resolved
- Developmental milestones: MaxA for all activities (age appropriate)

AS 5: Screen Infants for Non-muscular Causes of Asymmetry and Conditions Associated with CMT[1]

- Obtain history
- Systems Screen: Cranial nerve, coordination, tone, alignment, and developmental delay
  - Musculoskeletal
    - Symmetry of face, skull, and spine. Alignment of shoulders and hip girdles. Hip dysplasia, PROM of neck, and palpation for SCM masses
  - Neurological
    - Tone, primitive reflexes, resistance to movement, cranial nerves, brachial plexus, visual screen, temperature, developmental milestones
  - Integumentary
    - Skin fold symmetry of hips and neck, color and condition of skin

AS 5: Screen Infants

- Cardiorespiratory
  - Symmetrical coloration, rib cage expansion, clavicle movement, acute upper respiratory tract distress, wheezing
- Gastrointestinal
  - Parent report for reflux or constipation, preference to feeding on one side

AS 5: Screen Infants

- Findings warranting referral[1]
  - Cranial and/or facial asymmetry
  - Atypical presentation
  - Abnormal tone
  - Late-onset torticollis
  - Visual abnormalities
    - Nystagmus, strabismus, limited tracking, or gaze aversion
  - Acute onset
  - Suspected developmental dysplasia of hip
  - Infant color change during PROM assessment
  - 12+ months and facial asymmetry and/or 15 degree difference; 7+ months with SCM mass

Case AS 5: Screen Infants

Body System	Details
Musculoskeletal	No palpable nodules present. Prefers looking L in all positions. Moves arms and legs without difficulty
Neurological	Normal UE/LE tone. Visual tracking intact
Integumentary	R neck intact with mild redness at skin folds. Provided education to keep area clean
Cardiorespiratory	Right ventricular hypertrophy: resolved as per cardiologist
Gastrointestinal	Negative GERD, breast feeds bilaterally.

AS 6: Refer Infants from PT to Physician if Indicated by Screen

- Roughly 18% are non-muscular causes[14]

Red Flags
Poor visual tracking
Abnormal muscle tone
Extramuscular masses
Asymmetries inconsistent with CMT
Little improvement in neck symmetry following 4-6 weeks on intervention

Non-Muscular Causes
Klippel-Feil Syndrome
Neurologic disorders
Ocular disorders
Brachial plexus injuries
Clavicle fractures
Paroxysmal torticollis
Spinal abnormalities
SCM masses

Case AS 6: Refer Infants from PT to Physician if Red Flags are Identified

- No red flags present

AS 7: Request Images and Reports

- Obtain all images and reports
  - May have notes from specialists for ocular, neurological, skeletal, and oncological concerns
    - Help to rule out non-muscular causes
  - Ultrasound may have been conducted if SCM mass was detected by the pediatrician

Case AS 7: Request Images and Reports

- Mother verbally reports that patient has seen a cardiologist and that his heart concerns are no longer present
- Referral note comes with well child note attached
  - Physician note reports typical development at this time
- In the case of a suspected mass detected by the PT, contact the physician to set up a follow-up for ultrasound

PT Examination

8. Examine Body Structures
9. Classify the level of severity
10. Examine activity and developmental status
11. Examine participation status
12. Determine prognosis

AS 8: Examine Body Structures

- General posture and tolerance in supine, prone, sitting, and standing
  - Supine
    - Side of torticollis, hip positions, craniofacial asymmetries, restricted AROM, use of trunk and extremities. Degree of torticollis via photograph
  - Prone
    - Head relative to trunk, spine, scoliosis, asymmetrical use of extremities, tolerance to position
  - Sitting
    - Head position, compensations in shoulders, trunk, and hip

Screen Scales

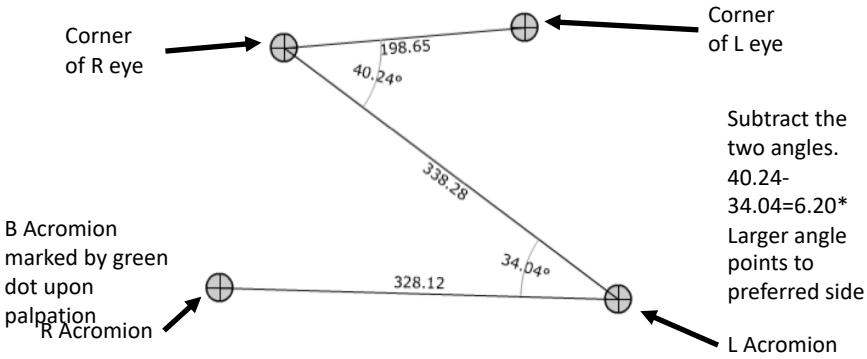

Subtract the two angles. 40.24-34.04=6.20* Larger angle points to preferred side

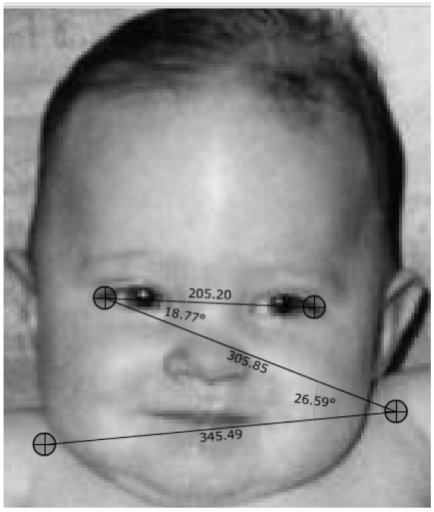

26.59 – 18.77 = 7.82* R tilt

AS 8: Examine Body Structures

- Bilateral cervical rotation and lateral flexion PROM
  - Arthrodial protractor
    - Ideally 2 adults: Stabilize trunk on support surface and other rotates head and performs lateral flexion
    - PTs often use visual estimate
  - Modification or avoidance: osteogenesis imperfecta, congenital hemivertebrae, Down Syndrome with unknown cervical stability
    - Recommended gentle guidance

AS 8: Examine Body Structures

- Cervical AROM
  - Difficult due to behavior
  - Relied heavily on visual measurement
  - Birth to 3 months: Supine[15]
  - 3+ months: sitting in clinician's lap
    - Rotating Stool test
  - 2+ months: Muscle Function Scale for lateral flexion[16]

Muscle Function Scale

- Testing: Hold infant vertically in front of mirror with arthrodial protractor
- Scoring
  - 0: Does not reach midline
  - 1: Obtains 0 degrees/midline
  - 2: 0-15 degrees
  - 3: 15-45 degrees
  - 4: 45-75 degrees
  - 5: 75+ degrees[16]

AS 8: Examine Body Structures

- Trunk and extremity AROM & PROM
  - Spine, shoulders, hips, arms, legs
  - Natural movements and PROM
- Assesses for brachial plexus injuries, clavicle fracture, neurological impairment, hypermobility, or CNS issues[1]
- CMT and hip dysplasia: 2.5% to 17%

Hip Dysplasia

- Increased risk for the following
  - Breech position
  - Cesarean delivery
  - Family history
  - Maternal age less than 20 years
  - Apgar <8 at 1 minute
  - Female
- To assess
  - <3 months: Ortolani and Barlow maneuvers
  - 3+ months: Galeazzi sign (limb asymmetry) and hip abduction PROM restrictions

AS 8: Examine Body Structures

- Document infant pain or discomfort at rest and during passive & active movement
  - Preferred method is the FLACC scale
    - 2 months to 7 years of age
    - Facial expressions, movement, and behavior state with a 3 point scale and max of 10 points
      - 0: no expression or quiet state
      - 1: Occasional expression
      - 2: Inconsolable
  - Quick assessment via handing child back to parent and assess how quickly the infant calms down

AS 8: Examine Body Structures

- Skin and muscle integrity
  - Symmetry of neck and hips
    - Redness
  - Palpate bilateral SCM muscles
    - Record mass if present
  - Upper trap tightness[17]
  - Hiking of shoulder of affected side

AS 8: Examine Body Structures

- Craniofacial asymmetries
  - May affect jaw, cheekbones, orbital, and ear positions[1]
  - Frontal, temporal, parietal, and occipital bones
  - Plagiocephaly vs brachycephaly vs scaphocephaly
  - 90.1% prevalence of craniofacial asymmetry with CMT[18]
  - Refer if concerns of craniosynostosis[19]
    - Inconsistent findings of plagiocephaly or brachycephaly

Case AS 8: Examine Body Structures

- Infant posture and tolerance in supine, prone, sitting, and standing
  - At rest, patient's head consistently right tilted
  - Patient prefers to look to left
  - Resting head tilt measured via Screen Scales: 5.86* R tilt
- Bilateral cervical rotation and lat flexion PROM & AROM

Direction	PROM	AROM
L rotation	**90***	90* (sup, prone, sitting)
R rotation	**80***	60* (sup, prone, sitting)
L lateral flexion	50*	-10*
R lateral flexion	60*	5*

Case AS 8: Examine Body Structures

- Passive and active ROM of upper and lower extremities
  - Normal
- Pain or discomfort at rest and during passive or active ROM
  - None noted. Some resistance to movement
  - Stretching analogy to parents

Case AS 8: Examine Body Structures

- Skin integrity, symmetry of folds, presence of SCM mass, and size, shape, & elasticity of SCM
  - Mild redness in R neck skin folds, but no breakdown
- Craniofacial asymmetries and head shape
  - Mild flattening of L occipital region, no anterior bossing
  - Potential head scan referral

continued

AS 9: Classify the Level of Severity

Grade	Age At Evaluation	PROM Rotation Restriction
I: Early Mild	0-6 months	<15*
II: Early Moderate	0-6 months	15-30*
III: Early Severe	0-6 months	>30* or SCM mass
IV: Later Mild	7-9 months	Postural or <15*
V: Later moderate	10-12 months	Postural or <15*
VI: Later Severe	7-9 months	15-30* or >30*
VII: Later Extreme	7-12 months OR	SCM mass OR
	10-12 months	>30* or SCM mass
VIII: Very Late	12+ months	Postural, muscle tightness, or SCM mass

continued

Case AS 9: Classify the Level of Severity

- Presents at 2 months
- Lacking 10* cervical rotation compared bilaterally
- No SCM mass
- What classification level would the patient be under?

AS 10: Examine Activity and Developmental Status

- Motor delays as early as 2 months
  - Prevalence at 2 and 6 months
  - Typically resolves 8-15 months of age
- Many resolve by 8-15 months
- Tolerance to position changes
- Examine gross motor development

Examine Gross Motor Development

- Looking for movement symmetry and milestones
- Rolling, POE, POEE, sitting, supported sitting, PTS/rev-PTS, body control in supine, prone, and sitting, HRing, and HRing during rolling.

Gross Motor Assessment Tools

- Test of Infant Motor Performance: Birth-4 months
- Alberta Infant Motor Scale: 1-18 months or until walking
- Gross Motor subtest of the Peabody Developmental Motor Scales, 2nd edition: 1-72 months of age

Case AS 10: Examine Activity and Developmental Status

- Did not perform any standardized gross motor assessment
- Prone: Able to perform ¼ neck extension for brief periods
  - 0-30 second tolerance
- Supine: Can maintain midline head position if place there, B UE movement to midline, and LE movement
- Head lag during PTS/rev-PTS is greater than 45*

Position	Level of Assist
Static POE	Moderate
Weight shifting in POE	Max
B Rolling supine<>prone	Max
Supported sitting	Min to moderate

AS 11: Examine Participation Status

- Positioning when awake and asleep, and prone position
  - Plagiocephaly prevention
  - Correct postural preference
  - Treat CMT if present
- Position prevention
  - Prone positioning
  - Asymmetrical handling to activate weak neck musculature
  - AROM to limited side
    - Feeding alternate sides

AS 11: Examine Participation Status

- Purposeful positioning
  - Promotes symmetrical head shape development[20]
  - Cervical AROM and PROM
  - Tolerance to prone
  - Achievement of motor milestones

AS 11: Examine Participation Status

- Feeding
  - Feeding positions
  - Feeding issues: asymmetrical jaw positioning, preference for side of nursing
  - 44%: Feeding side preference
  - 2.4%: Additional feeding problems
    - Infants who breastfeed bilaterally have a lower incidence of CMT and CD

AS 11: Examine Participation Status

- Equipment/positioning devices
  - Limit time spent in positioning equipment
  - Can cause cranial deformity and subsequent CMT
  - Education on alternating toys and placement in cribs
  - Education on alternative prone activities
    - Prone on chest, wedge, & therapy ball

CONTINUED

Case AS 11: Examine Participation Status

- Feeding
  - Eats bilaterally
  - Increased difficulty to the R but still able to eat
- Sleep Positions
  - Prefers to look L when sleeping
    - Mother adjusts head when sleeping, but reverts back to R rotation
- Time spent in prone
  - Two 10 minute sessions throughout the day
- Time spent in equipment
  - Patient rarely in equipment. Mother carries him consistently
  - Mother positions toys to R side to promote looking to that side

CONTINUED

AS 12: Determine Prognosis

- Determine length of episode of care
- Communicate with parents/caregivers
- Further referral for more invasive interventions if unresolved following physical therapy

Symptom Resolution Factors

1. Participation in physical therapy
2. Younger age at referral
3. Decreased different in cervical rotation PROM
4. Decreased difference in SCM thickness
5. Home exercise program compliance
   - Passive stretching
   - Active positioning

Longer Care Factors

1. Older age at referral
2. Increased restriction of neck rotation PROM
3. Increased head tilt at rest
4. Motor asymmetry
5. Increased thickness or stiffness of SCM
6. Presence of SCM mass or lesion
7. Delivery history of lower birth weight and breech position

Case AS 12: Determine Prognosis

- Prognosis
  - Given young age, provided stretching HEP and begin treatment sessions in 4 weeks
    - Hold to allow for focused stretching at home and allow for additional natural neck strength and head control development
  - 1x/wk for 12 weeks

Physical Therapy Intervention

13. Provide the 5 components of first-choice interventions
14. Provide supplemental interventions, after appraising appropriateness for the infant, to augment the first-choice intervention
15. Refer for consultation when outcomes are not fully achieved

AS 13: Provide the 5 Components of First-Choice Interventions

- Neck PROM
  - Manual stretching
    - 100 vs 50 stretches
    - No consensus on duration or reps
  - Low-intensity, sustained, and pain-free[21]
  - Positioning and handling
  - Should stop if child resists or breathing/circulation changes
  - Can be performed in supine, side-lying, or prone
  - Encourage alternative feeding positions

AS 13: Provide the 5 Components of First-Choice Interventions

- Neck and trunk active ROM
  - Righting reactions: upright, rolling, sidelying, and sitting
  - Visual and auditory tracking to assist in rotation
- Development of symmetrical movement
  - Motor asymmetry: Up to 25%[22]
    - 2/3 no asymmetry at 2 years
  - Static and dynamic tasks in supine, prone, sitting, creeping, and walking

AS 13: Provide the 5 Components of First-Choice Interventions

- Environmental adaptations
  - Crib, car seat, play area, and changing table positioning
  - Placing toys on opposite side
- Parent/caregiver education
  - Sell tummy time!
  - Positioning and handling
  - Minimizing "baby baskets"
  - Alternating feeding sides

Case AS 13: Provide First Choice Interventions

1. Neck PROM
   - Snuggle stretch to R rot
   - Supine stretch to R rot
   - Football hold for L lateral flexion
   - Football hold for L lat flexion and R rot

Case AS 13: Provide First Choice Interventions

2. Neck and Trunk AROM
   - Active rot tracking in supine, prone, and sitting
     - Following toys, faces, sounds, etc
   - Head righting
     - Via football hold, sitting on knees, or therapy ball
   - Pull to sit & reverse pull to sit
   - Prone on elbows
   - Prone on extended elbows
   - Reaching for toes

Case AS 13: Provide First Choice Interventions

3. Development of symmetrical movement
   - Rolling bilaterally supine<>prone
   - Reaching (mat and shoulder level) in POE/POEE bilaterally on mat and on ball
   - Forward and lateral prop sitting with active reaching
   - POE with support (ie towel or wedge) as needed

Case AS 13: Provide First Choice Interventions

4. Environmental Adaptations
   - Toys and play to the right side
   - Siblings aware and play on his right side
   - Reaching across midline with both hands for toys
   - Various play positions
     - Supine, POE, POEE, sitting, sidelying, arm propped sitting, etc

Case AS 13: Provide First Choice Interventions

5. Parent Education
   - This is PIVOTAL for infants with torticollis
   - Typically only seen 1x/week in the clinic
     - 0.59% of infant's week is spent with therapist!
   - Provide thorough HEP: General care handout, stretches, POE/POEE on wedge, fwd and lat prop sitting, facilitated rolling, PTS/rev-PTS
     - Stretches: Perform at every diaper change. Some successes, some failures

AS 14: Provide Supplemental Interventions

- Adjuncts to the first choice interventions
- Utilized for several reasons
  - First choice has not improved ROM or postural alignment
  - Access to services is limited
  - Infant does not tolerate intense therapy
  - PT has appropriate training to administer intervention

AS 14: Provide Supplemental Interventions

- Level I Evidence
  - Microcurrent
  - Kinesiological Taping
  - Myokinetic stretching
  - Soft Tissue Mobilization
- Level IV Evidence
  - TAMO
- Level V Evidence
  - Tubular orthosis for torticollis (TOT) collar
  - Soft foam collars
  - Custom-fabricated cervical orthoses

CONTINUED

Level I Evidence

- Microcurrent
  - Low-intensity alternating current
  - Applied to affected SCM
  - 3x/wk for 2 weeks were shown to improve tilt angle, neck rotation, and less crying during therapy[23]
  - MC Randomized trial[24]
    - MC group: 2.6 months of care
    - Control: 6.3 months of care

CONTINUED

Level I Evidence

- Kinesiological Taping
  - Supports muscles and provides sensory feedback
  - For use during muscle relaxation of tight muscles, facilitation of weakened side, or combination of both
  - No significant difference between treatment groups (facilitation and/or inhibition) after treatment, 1 month, or 3 month post treatment[25]
  - Findings show improvements on MFS scores while tape is applied[26]

continued

Level I Evidence

- Soft Tissue Mobilization
  - Passive mobilization, mobilization with stretching, and mobilization with active rotation
  - Improved cervical rotation PROM and head tilt after 6 weeks but not 12 when compared to control with HEP
  - Unclear findings due to poor explanation and frequency of control

continued

Level I Evidence

- Myokinetic Stretching[27]
  - Sustained 2-finger overpressure on taught SCM
  - 60 reps over 30 minute period 5x/wk for an average of 1.7 months
  - Results show significant reduction in SCM thickness, improved cervical rotation, and head symmetry

Level IV Evidence

- TAMO (Tscharnuter Akademie for Motor Organization)
  - Emphasizes light touch and infant's response to gravity and support surfaces
  - Requires postgraduate training

Level V Evidence

- TOT collars
  - Neck orthotic to prevent movement toward and stimulate active movement away from tilted side
  - Used on infants aged 4-4.5 months who have adequate head control in sitting and demonstrate >5-6* head tilt

continued

Level V Evidence

- Soft collar
  - Passive support following surgery
- Custom fabricated cervical orthoses
  - Utilized following surgery
  - Provides greater stability and less mobility than soft collars

continued

AS 14: Provide Supplemental Interventions

- Interventions without evidence of efficacy
  - Cervical manipulation
  - Soft tissue massage
  - Craniosacral therapy
  - Total Motion Release
  - Feldenkrais
- Not recommended for treatment due to lack of evidence[1]

Case AS 14: Provide Supplemental Interventions

- Patient responded very well to first-choice interventions
- Did not require the use of supplemental interventions

AS 15: Refer for Consultation when Outcomes are not Fully Achieved

- Consult physician or specialists about alternative interventions when infant is not progressing

Reasons to Refer
Asymmetries of head, neck, and trunk persist after 4-6 weeks of initial therapy
After 6 months of treatment with moderate resolution
Infant is 12 months or older at evaluation with facial asymmetry and/or 10-15* difference
Infant is 7 months or older at evaluation with tight band or SCM mass
Torticollis changes sides

AS 15: Refer for Consultation when Outcomes are not Fully Achieved

- Duration of care
  - CMT Classification 1-3: <6 months
  - CMT Classification 3-7: 6+ months
    - Other factors: Age at referral, motor asymmetries, presence of SCM mass, head tilt, quality of SCM fibers, facial asymmetry, parent compliance, and other infant health conditions

AS 15: Refer for Consultation when Outcomes are not Fully Achieved

- Invasive procedures warranted with lack of progress in 6 months or begins intervention at 1+ year of age with significant restriction or SCM mass[1]
  - Botox
    - Effectiveness: 25% to 74% to 93%[17,28,29]
    - Adverse effects: Pain, bruising, temporary dysphagia, and neck weakness
      - All resolve over time
  - Surgery
    - Tendon lengthening
    - Unipolar release of distal SCM attachment
    - Bipolar release of both muscle attachments

continued

Indications for Surgery

- Decreased cervical ROM 15* or greater
- Progressing limitations
- SCM mass older than 12 months
- Persistent head tilt
- Not responding to treatment for 6 months
- Reaching year 1 without resolution
- Post-op management
  - 4-6 weeks to 4 months
  - Scar management, muscle strength, and ROM

continued

Case AS 15: Refer for Consultation when Outcomes Not Achieved

- Patient had good outcomes and did not need any additional referrals

CONTINUED

Physical Therapy Discontinuation, Reassessment, and Discharge

16. Document outcomes and discharge infants from physical therapy when criteria are met
17. Provide follow-up screening of infants 3-12 months post-discharge

CONTINUED

AS 16: Document Outcomes and Discharge Infants from PT When Criteria are Met

- Document measurements at end of care
- Discharge is warranted when:
  - Full PROM is within 5* of the unaffected side
  - Symmetrical active movement patterns
  - Age-appropriate motor development
  - No visible head tilt
  - Parents understand what to monitor

Case AS 16: Document Outcomes and Discharge Infants

- ~6 months old at discharge (12 visits total)
- Full PROM is within 5* of the unaffected side
  - Full PROM for B cervical rot and lat flexion
- Symmetrical active movement patterns
  - 10* L HRing and 20* R HRing in anti-gravity position
    - Stressed to continue tilt in space for HEP
  - 90* B rot supine
  - 85* B rot prone and sitting

Case AS 16: Document Outcomes and Discharge Infants

- Age-appropriate motor development
  - MinA to reach in POEE
  - Rolling independently
  - Reaching in POE
  - Sitting with CGA
  - Prop sitting with CGA
- Head tilt
  - 0.24* R tilt
- Parents understand what to monitor
  - Mother educated on symmetry and provided with handouts for future skills such as tall kneeling, 4 pt with support, and B side sitting.

AS 17: Provide Follow-up Screening of Infants 3-12 Months Post-Discharge

- Reassess for:
  - Positional preference
  - Structural and movement symmetry of the neck, face, head, trunk, hips, UEs, LEs, and developmental milestones
- Persistent CMT may result in asymmetrical gross motor development
- Excellent outcomes are having <5* head tilt
- Good outcomes are 5-10* head tilt
- Refer to early intervention services

AS 17: Provide Follow-up Screening of Infants 3-12 Months Post-Discharge

- Preschool age[30]
  - No motor delays
  - 7% head tilt preference
  - 26% PROM asymmetry
- Risk of:
  - Muscle fibrosis, developmental delays, and hemisyndrome[1]

Case AS 17: Provide Follow-up Screening

- Follow up typically conducted by physician
- Formal follow-up resulted in typically developing child with age appropriate gross motor skills and good cervical AROM
  - Educated on promoting symmetry as patient continues to learn more skills

Conclusion

- Although the Clinical Practice Guidelines can be daunting to tackle, all of the information is extremely clinically relevant
- Provides great summary of Action Statements as a quick reference
- Thorough examination and evaluation recommendations
  - May seem like a lot, but all info can be gathered easily within 1 hour
- Provides several options if first-choice interventions aren't successful

CONTINUED

Questions???

CONTINUED

References

1. Kaplan SL, Coulter C, Fetters L. Physical therapy management of congenital muscular torticollis: an evidence-based clinical practice guideline: from the Section on Pediatrics of the American Physical Therapy Association. *Pediatr Phys Ther.* 2018;30(4):240-290.
2. Chen M-M, Chang H-C, Hsieh C-F, Yen M-F, Chen TH-H. Predictive model for congenital muscular torticollis: analysis of 1021 infants with sonography. Arch Phys Med Rehabil. 2005;86(11):2199-2203.
3. Aarnivala HEI, Valkama AM, Pirttiniemi PM. Cranial shape, size and cervical motion in normal newborns. Early Hum Dev. 2014;90(8):425-430.
4. Cheng JC, Tang SP, Chen TM. Sternocleidomastoid pseudotumor and congenital muscular torticollis in infants: a prospective study of 510 cases. J Pediatr. 1999;134(6):712-716.
5. Petronic I, Brdar R, Cirovic D, et al. Congenital muscular torticollis in children: distribution, treatment duration and outcome. Eur J Phys Rehabil Med. 2010;45(2):153-158.
6. Cheng JC, Chen TM, Tang SP, Shum SL, Wong MW, Metreweli C. Snapping during manual stretching in congenital muscular torticollis. Clin Orthop Relat Res. 2001;384:237-244.
7. Hagan JF, Shaw JS, Duncan PM. Bright Futures: Guidelines for Health Supervision of Infants, Children and Adolescents. 3rd ed. Elk Grove Village, IL: American Academy of Pediatrics; 2008. ISBN 9781581102239.
8. Koren A, Reece SM, Kahn-D'angelo L, Medeiros D. Parental information and behaviors and provider practices related to tummy time and back to sleep. J Pediatr Health Care. 2003;24(4): 222-230.
9. McAllister JM, Hall ES, Hertenstein GER, Merhar SL, Uebel PL, Wexelblatt SL. Torticollis in infants with a history of neonatal abstinence syndrome. J Pediatr. 2018;196:305-308.
10. Demirbilek S, Atayurt HF. Congenital muscular torticollis and sternomastoid tumor: results of nonoperative treatment. J Pediatr Surg. 1999;34(4):549-551.
11. Öhman AM, Nilsson S, Beckung ERE. Stretching treatment for infants with congenital muscular torticollis: physiotherapist or parents? A randomized pilot study. PM R. 2010;2:1073-1079.
12. Stellwagen LM, Hubbard E, Vaux K. Look for the "stuck baby" to identify congenital torticollis. Contemp Pediatr. 2004;21(5):55-65.

CONTINUED

References

13. Jung AY, Kang EY, Lee SH, Nam DH, Cheon JH, Kim HJ. Factors that affect the rehabilitation duration in patients with congenital muscular torticollis. Ann Rehabil Med. 2015;39(1):18-24.
14. Ballock RT, Song KM. The prevalence of nonmuscular causes of torticollis in children. J Pediatr Orthop. 1996;16:500-504.
15. Laughlin J, Luerssen TG, Dias MS. Prevention and management of positional skull deformities in infants. Pediatrics. 2011;128(6):1236- 1241.
16. Öhman AM, Nilsson S, Beckung ER. Validity and reliability of the Muscle Function Scale, aimed to assess the lateral exors of the neck in infants. *Physiother Theory Pract*. 2009;25(2):129-137.
17. Oleszek JL, Chang N, Apkon SD, Wilson PE. Botulinum toxin type a in the treatment of children with congenital muscular torticollis. *Am J PhysMedRehabil*.2005;84(10):813-816.
18. Cheng JC, Tang SP, Chen TM, Wong MW, Wong EM. The clinical pre- sentation and outcome of treatment of congenital muscular torticollis in infants—a study of 1,086 cases. *J Pediatr Surg*. 2000;35(7):1091- 1096.
19. Cunningham ML, Heike CL. Evaluation of the infant with an abnormal skull shape. *Curr Opin Pediatr*. 2007;19:645-651.
20. de Chalain TMB, Park S. Torticollis associated with positional plagiocephaly: a growing epidemic. J Craniofac Surg. 2010;16(3): 411-418.
21. van Vlimmeren LA, Helders PJM, van Adrichem LNA, Engelbert RHH. Torticollis and plagiocephaly in infancy: therapeutic strategies. *Pediatr Rehabil.* 2006;9:40-46.
22. Watemberg N, Ben-Sasson A, Goldfarb R. Transient motor asymmetry among infants with congenital torticollis—description, characteriza- tion, and results of follow-up. *Pediatr Neurol*. 2016;59:36-40.
23. Kim MY, Kwon DR, Lee HI. Therapeutic effect of microcurrent therapy in infants with congenital muscular torticollis. *Phys Med Rehabil*. 2009;1(8):736-739.
24. Kwon DR, Park GY. Ef cacy of microcurrent therapy in infants with congenital muscular torticollis involving the entire sternocleido- mastoid muscle: a randomized placebo-controlled trial. *Clin Rehabil*. 2014;28(10):983-991.

CONTINUED

References

25. Giray E, Karadag-Saygi E, Mansiz-Kaplan B, Tokgoz D, Bayindir O, Kayhan O. A randomized, single-blinded pilot study evaluating the effects of kinesiology taping and the tape application techniques in addition to therapeutic exercises in the treatment of congenital muscular torticollis. Clin Rehabil. 2017;31(8):1098-1106.
26. Öhman A. The immediate effect of kinesiology taping on muscular imbalance in the lateral flexors of the neck in infants: a randomized masked study. PM R. 2015;7(5):494-498.
27. Chon SC, Yoon SI, You JH. Use of the novel myokinetic stretching technique to ameliorate brotic mass in congenital muscular torticollis: an experimenter-blinded study with 1-year follow-up. J Back Musculoskelet Rehabil. 2010;23:63-68.
28. Joyce MB, de Chalain TMB. Treatment of recalcitrant idiopathic muscular torticollis in infants with botulinum toxin type a. J Craniofac Surg. 2005;16(2):321-327.
29. Collins A, Jankovic J. Botulinum toxin injection for congenital muscular torticollis presenting in children and adults. *Neurology*. 2006;67:1083-1085.
30. Öhman A, Beckung E. Children who had congenital torticollis as infants are not at higher risk for a delay in motor development at preschool age. *PM R*. 2013;5(10):850-855.