

If you are viewing this course as a recorded course after the live webinar, you can use the scroll bar at the bottom of the player window to pause and navigate the course.

This handout is for reference only. It may not include content identical to the powerpoint. Any links included in the handout are current at the time of the live webinar, but are subject to change and may not be current at a later date.

# Wrist Instability

Ellen Pong DPT, MOTR/L

## Learner Outcomes

**As a result of this course, participants will be able to:**

- 1) ...identify the bony anatomy and major ligamentous structures that are relevant to wrist instability.
- 2) ...recognize three basic patterns of wrist instability, terms that identify carpal alignment on films; and the Mayo Clinic system of carpal instability classification groups.
- 3) ...incorporate evidence-based clinical assessments for wrist instabilities into their clinical practice.
- 4) ...discuss current knowledge in conservative treatments for wrist instability, state the potentials and limitations of these treatments, and confidently explore novel custom splinting for this pathology in their clinical practice.

## Introduction: Function

Why are we concerned with stability of the wrist? Why is this such an important element of functional use of the arm and hand? The wrist provides a crucial link between powerful use of the forearm and precision use of the hand.



Image by Author

## Introduction: Grasp Mechanisms

Even a simple grasp of an object requires at least four mechanisms of carpal stabilization:

1. the proximal carpal row
2. the distal carpal row
3. the midcarpal joint
4. the radiocarpal joint

(Garcia-Elias, 1997a)

## Introduction: Stability for Fine and Gross Motor



Image by Author

Stability of the radial side must support opposable thumb use, while stability of the distal radioulnar joint must support forearm rotation in tool use and carrying (Dobbs, 2003).

## Introduction: Definition

Wrist instability has been defined as **a wrist having altered kinematics and/or being unable to support physiological loads** (Lichtman & Wroten, 2006; Linscheid & Dobyns, 2002), and further clarified as **instability that occurs from all untreated dislocations and displaced or mal-united fractures** (De Filippo et al, 2006).

## Introduction: Joints

Although four joints may be considered in presentation of wrist instability: carpometacarpal joint, midcarpal joint, radiocarpal joint and distal radioulnar joint (DRUJ) (Dumontier, 1996), **this course will explore midcarpal, radiocarpal, and DRUJ instability.**

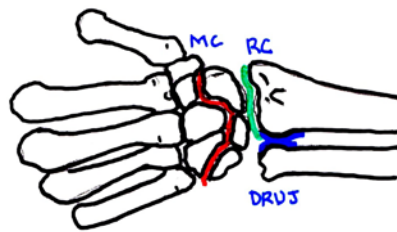


Image by Author

## Anatomy: Joints

The distal radius forms a large articular surface for the scaphoid and lunate, which creates the radiocarpal joint (Wadsworth, 1988).

The distal radioulnar joint (DRUJ) is formed between the distal ends of the radius and ulna.

**The DRUJ is vulnerable to translational dorsal and volar instability due to the incongruity of its articular surfaces.** (Kleinman, 2007).

## Anatomy: Joints

The distal ulna also contains an articular surface with the triangular fibrocartilage complex (TFCC) (Dobbs, 2003).

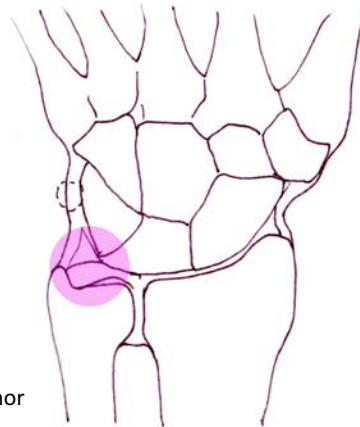


Image by Author

## Anatomy: Carpals

The carpals are divided into proximal and distal rows. The proximal row contains the scaphoid, lunate, triquetrum, and pisiform. **Proximal row carpals move with greater degrees of rotation to each other than do those of the distal row.** The trapezium, trapezoid, capitate and hamate make up the more stable distal row (Schmitt et al., 2006). **The lunate is the most frequently dislocated carpal, most often dorsal to the scaphoid.** (Wadsworth, 1988; Schmitt et al., 2006).

## Anatomy: Carpals

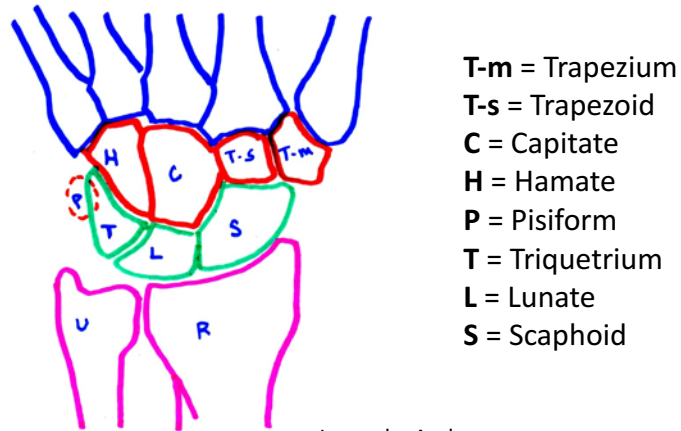


Image by Author

## Anatomy: Midcarpal Joint

The midcarpal joint is described by some as a combination of three joints: **the scaphotrapezoid-trapezial (STT); the capitrolunate central compartment; and the hamatotriquetral medial compartment** (Schmitt et al., 2006).

Others describe it as the scaphocapitate/lunocapitate central articulation and the triquetrohamate medial articulation (Shin, 2008).

## Anatomy: Ligament Stabilization

Descriptions of the wrist ligaments have some disagreement; however, they are generally described as **intrinsic or extrinsic, palmar or dorsal, and intracapsular** (meaning thickenings of the joint capsule) (Caggiano & Matullo, 2014).

The distal row carpals have little motion between them due to strong intercarpal ligaments. The trapezium and capitate are ligamentously bound to the index and middle metacarpals. In this way **the distal row can be considered as part of a fixed unit of the hand that moves responsively with the musculotendinous forces of the forearm.**

## Anatomy: Intercalated Segment

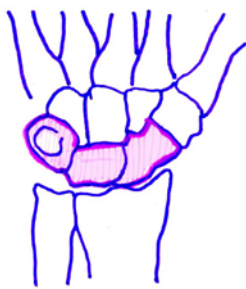

Image by Author

**No tendons insert on the intercalated segment composed of the scaphoid, lunate, and triquetrum.** The motion of this segment derives mechanically from the surrounding articulations, and is stabilized the extensive network of intrinsic, or interosseous, and extrinsic carpal ligaments (Kitay & Wolfe, 2012).



## Anatomy: Major Ligaments

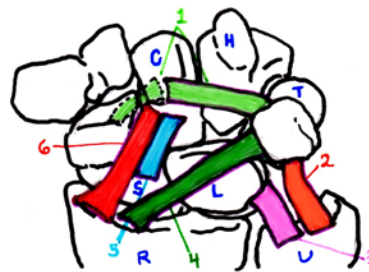
Important Ligaments of the Wrist			
Position	Ligament	Abbreviation	Functional Importance
<b>Interosseous</b>	Scapholunate ligament	SLL	PCR stabilizer
	Lunotriquetral ligament	LTL	PCR stabilizer
	Radioscaphoid ligament	RSL	Volar scaphoid stabilizer
	Radioscapholunate ligament	RSLL	Neurovascular bundle
	Radiolunate ligament (short RL ligament)	RLL	Volar lunate stabilizer
<b>Volar Proximal V</b>	Volar radiolunotriquetral ligament (long RL ligament)	vRLTL	Radiocarpal stabilizer ("slingshot")
	Ulnotriquetral ligament	UTL	Ulnocarpal stabilizer
	Ulnolunate ligament	ULL	Ulnocarpal stabilizer
<b>Volar Distal V</b>	Radioscaphocapitate ligament	RSCL	Radiocarpal and scaphoid stabilizer "slingshot," "supporter"
	Scaphocapitate ligament	SCL	Midcarpal stabilizer
	Triquetrocipitatoscapoid (arcuate) ligament	TCSL	Midcarpal stabilizer
	Scaphotrapezotrapezoidal ligament	STTL	Scapholunate stabilizer
<b>Dorsal V</b>	Dorsal radiolunotriquetral ligament	dRLTL	Radiocarpal stabilizer "slingshot"
	Dorsal intercarpal ligament	dICL	Midcarpal stabilizer

Adapted from: (Schmitt et al, 2006)

\*PCR = proximal carpal row

## Anatomy: Major Volar Ligaments

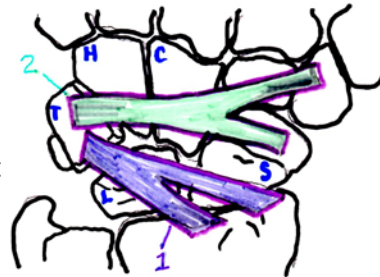
1. triquetrocipitatoscapoid ("arcuate") ligament (TCSL)
2. ulnotriquetral ligament (UTL)
3. ulnolunate ligament (ULL)
4. volar radiolunotriquetral ligament (vRLTL)
5. scaphocapitate ligament (SCL)
6. radioscaphocapitate ligament (RSCL)



Adapted from: (Schmitt et al, 2006)

## Anatomy: Major Dorsal Ligaments

1. dorsal radiolunotriquetral ligament (dRLTL)
2. dorsal intercarpal ligament (dICL)

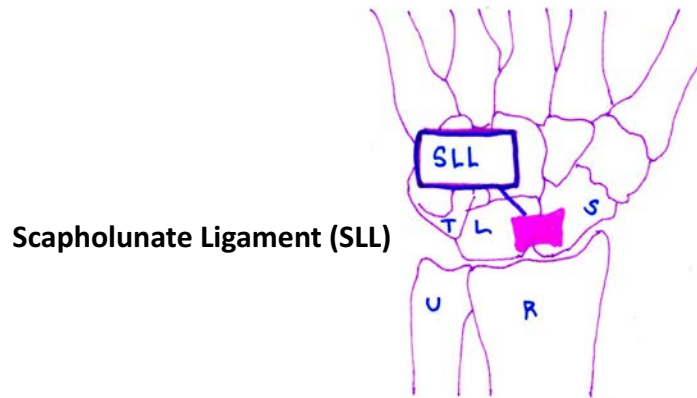


Adapted from: (Schmitt et al, 2006)

## Anatomy: SLL and LTL – Dissociative Instability

The **scapholunate (SLL) and lunotriquetral (LTL) ligaments stabilize the proximal carpal row** and are the most important stabilizers. Injury to the SLL and LTL results in scapholunate and lunotriquetral dissociation, which is termed “**dissociative instability.**” Specifically, **injury to the SLL produces the pattern of dorsal intercalated segment instability (DISI).** Injury to **both the SLL and LTL will result in volar intercalated segment instability (VISI)** (Caggiano & Matullo, 2014; Schmitt et al, 2006).

## Anatomy: SLL



Scapholunate Ligament (SLL)

Image by Author

## Anatomy: SLL Detailed Image

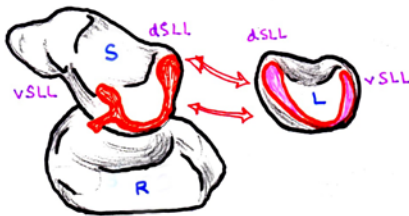


Image shows the medial aspect of the scaphoid with volar and dorsal segments of the SLL as well as the projection of the radioscapholunate ligament (RSLL). An “open book” view shows the lateral aspect of the lunate with the U-shaped SLL positioned. Dorsal and volar segments of the SLL are labeled. Adapted from: (Schmitt et al, 2006).

## Anatomy: SLL Details

The SLL has three segments. The center segment is composed of fibrocartilage that merges with the articular cartilage of the scaphoid and the lunate (Linscheid & Dobyns, 2002). **This middle segment does not have a stabilizing ability and is vulnerable to degenerative injury** (Ozcelik et al., 2005; Schmitt et al, 2006).

The **dorsal segment is the strongest and thickest of the three**, and functions as the main stabilizer of the scapholunate articulation (Caggiano & Matullo, 2014).

## Anatomy: LTL

The LTL is smaller than the SLL, but has a similar shape. Its middle segment is also vulnerable to degeneration and has no stabilizing ability. In the LTL, **it is the volar segment rather than the dorsal segment that provides functional stability of the lunotriquetral compartment** (Schmitt et al., 2006).

## Anatomy: Midcarpal Instability

Stabilizers of the midcarpal joint are the transversely crossing ligaments. **The triquetrocapitatoscapoid ligament (TCSL) and scaphocapitate ligament (SCL) provide volar stability, and the dorsal intercarpal ligament (dICL) provides dorsal stability.**

Smooth movement of the proximal row from flexion to extension in wrist ulnar deviation is produced by these ligaments, when intact. If injured, degenerated or lax, an axial load will push the proximal row into flexion. This is viewed as **midcarpal instability** (Schmitt et al., 2006).

## Anatomy: Axial Instability

**The flexor retinaculum and intercarpal ligaments provide stability to the distal carpal row.** Degradation of these transverse structures produces an instability that splits the wrist into two or three unstable columns; this is called **axial instability**.

**Translocation instability of the radiocarpal joint** is caused by rheumatoid arthritis or by **compromise of the radioscapaphcapitate (RSCL), volar radiolunotriquetral (vRLTL), and dorsal radiolunotriquetral (dRLTL) ligaments.** When intact, these ligaments prevent the carpus from sliding down along the ulnar and volar tilts of the radius (Schmitt et al., 2006).

## Anatomy: DRUJ Stabilizers

Extrinsic support of the DRUJ is provided by the interosseous mid-forearm ligament (Kleinman, 2007).

- 1. Interosseous mid-forearm ligament
- 2. Dorsal radioulnar ligament
- 3. Radial collateral and ulnar collateral ligaments

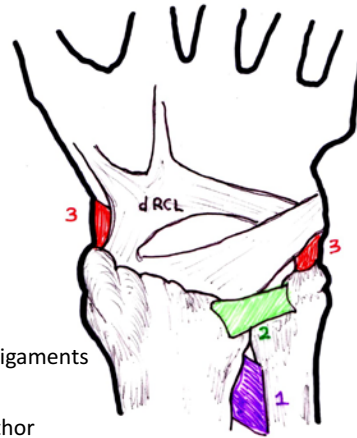
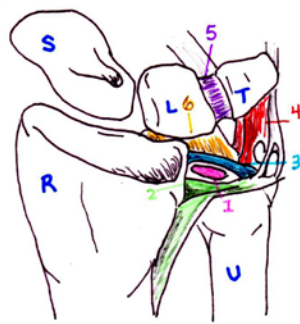


Image by Author

## Anatomy: TFCC Stabilizers



Adapted from:  
(Chong & Kandathil, 2013)

The intrinsic radioulnar dorsal and palmar ligaments provide stability for the TFCC (Kleinman, 2007).

- 1. Triangular disk
- 2. Dorsal radioulnar ligament
- 3. Volar radioulnar ligament
- 4. Ulnotriquetral ligament
- 5. Lunotriquetral ligament
- 6. Ulnolunate ligament

## Anatomy: Muscular Stabilizers

Despite having no direct tendon attachments to either of the carpal rows, there is a contribution of the wrist muscles to the stability of the carpus. Both **wrist flexors and extensors generate their maximum forces with the wrist fully extended, and are able to maintain a near-constant ratio of flexor to extensor torque over the full range of motion** (Lieber & Friden, 1998).

Although the flexors have a larger physiological cross-section area than do the extensors, the superior extensor moment over the flexor moment makes this ratio of stability possible. Additionally, the **tension of the extensor carpi ulnaris tendon across the ulna distal head combined with the superficial and deep heads of the pronator quadratus dynamically stabilizes the DRUJ** (Kleinman, 2007).

## Biomechanics: Forces

Without tendinous attachments on the proximal row, the **forces that act on the intercalated segment are dictated by the forces acting on its proximal and distal articular surfaces** (Caggiano & Matullo, 2014). This is initiated distally with tendons inserted at the base of the metacarpals. **Motion is initiated at the distal row, with forces traveling via carpals and competent ligaments to the proximal carpal row** (Bozentka, 1999).

## Biomechanics: Movements

Radial and ulnar deviation total range is an average of 45-50 degrees. Sixty percent of this movement occurs at the midcarpal joint, and the remaining forty percent is produced at the radiocarpal joint (Bednar & Osterman, 1993; DeFilippo et al., 2006).

Flexion-extension total range is an average of 121-150 degrees (Bednar & Osterman, 1993; DeFilippo et al., 2006), with the motion divided between the radiocarpal and midcarpal joints.

## Biomechanics: Oblique Wrist Motion

Traditional discussion of wrist movement has focused on motion running along the sagittal and coronal planes. An oblique wrist motion has been more recently supported from anatomical, anthropological, and biomechanical points of view.

**This wrist joint motion around an oblique axis is termed *dart thrower's motion*, or the *dart-throwing motion* (DTM) (Braidotti, Atzei & Fairplay, 2015).**



## Biomechanics: Oblique Wrist Motion

The dart thrower's motion takes place in the midcarpal joint, with the scaphotrapezoidtrapezial (STT) (also termed scaphotrapeziotrapezoid joint) being the primary joint that stabilizes and controls the DTM.

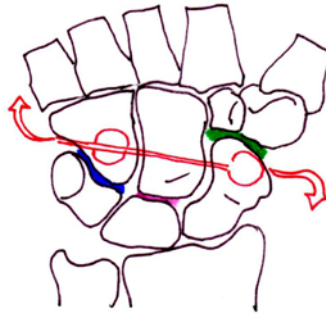
**DTM is produced as primarily midcarpal joint motion, with only minimal involvement of the radiocarpal joint and a nearly unchanged position of the lunate** (Braidotti, Atzei & Fairplay, 2015).

## Biomechanics: Oblique Wrist Motion

An important consideration is that the STT is a monoaxial joint, moving along an axis that parallels with the plane of the DTM; however, the directions of motion of the capitatolunate (lunocapitate) and hamatotriquetral (triquetralhamate) articulations somewhat differ among wrist flexion-extension, radioulnar motion and DTM (Braidotti, Atzei & Fairplay, 2015).

## Biomechanics: Oblique Wrist Motion

The axis of the DTM plane runs obliquely from the radiopalmar side of the scaphoid tuberosity to the ulnodorsal side of the hamate (Braidotti, Atzei & Fairplay, 2015).



Adapted from: (Braidotti, Atzei & Fairplay, 2015)

## Patterns

There are three basic patterns of instability, each being based on radiologic appearance:

*Pre-dynamic instability* - a clinical diagnosis with an apparently normal radiograph.

*Dynamic instability* - a clinical diagnosis supported by altered kinematics viewed on special but not standard radiographs. Malalignment occurs inconsistently when the carpals are loaded under certain conditions.

*Static instability* - a clinical diagnosis supported by altered kinematics appearing on conventional radiographs. The malalignment occurs with any amount of load applied. (Garcia-Elias, 1997b; Van Rooyen, 2005)

## Carpal Alignment on Films: DISI / VISI

Dorsal intercalated segment instability (DISI) and volar intercalated segment instability (VISI) are terms used to describe the position or alignment of the lunate in radiographs under conditions of carpal instability.

The longitudinal axes of the third digit metacarpal, capitate, lunate and radius should all fall on the same line. **If the lunate projects dorsally from this alignment, it is described as DISI. If the lunate extends volarly, it is termed VISI** (Carlsen & Shin, 2008).

## Classifications

The Mayo Clinic system of carpal instability classification groups instabilities according to pattern: *carpal instability dissociative* (CID), *carpal instability non-dissociative* (CIND), *carpal instability combined* (CIC), and *adaptive carpus instability* (CIA). It is currently the most widely known and used classification (Carlsen & Shin, 2008).

## Classifications: CID

Instability between individual carpals in the same row and involving the intrinsic ligaments is *carpal instability dissociative* CID (Bozentka, 1999). CID can occur within the proximal row (more commonly) or the distal row (uncommon). Distal row CID results from axial carpal dislocation, either radial or ulnar. Proximal row CID is radiographically seen with DISI deformity from a displaced scaphoid fracture or SLL dissociation or with VISI deformity as a result of LTL disruption. CID also includes combined proximal and distal row dissociation (Carlsen & Shin, 2008).

## Classifications: CIND

*Carpal instability non-dissociative* (CIND) describes instability between the proximal and distal carpal rows. This includes midcarpal instability, radiocarpal instability, or both. There is no specifically unifying injury pattern or pathology. It can accompany a generalized ligamentous laxity or hypermobility syndrome that does not necessarily involve trauma (Carlsen & Shin, 2008).

## Classifications: CIC

*Carpal instability complex (CIC)* is inclusive of injury patterns found in both CID and CIND, in which instability can be found both within a single carpal row as well as between rows. The most common injury in CIC involves perilunate dislocations, which occur with forced wrist extension, thenar impaction, ulnar deviation, and midcarpal supination (Carlsen & Shin, 2008).

## Classifications: CIC

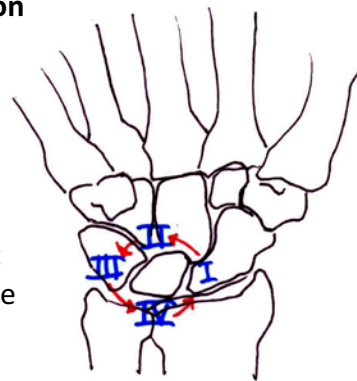
### Perilunate Dislocation Classification by Mayfield:

**Stage I:** partial disruption of the scapholunate ligament

**Stage II:** complete SLL injury and further capitulate dissociation

**Stage III:** Injury to the LTL ligament with scapholunate and capitulate dissociations

**Stage IV:** rupture of the dorsal radiocarpal ligament allowing the lunate to dislocate in a volar direction (Caggiano & Matullo, 2014)



Adapted from: Carlsen & Shin, 2008)

## Classifications: CIA

*Adaptive carpus instability* (CIA) is a secondary midcarpal instability, occurring due to the malposition of the carpus from malunion of the lunate or distal radius after fracture; nonunion of the scaphoid after fracture; or Madelung's deformity (Carlsen & Shin, 2008; Van Rooyen, 2005).

## Classifications: SLAC

Scapholunate advanced collapse (SLAC) is a form of osteoarthritis induced by chronic scapholunate ligament injury. Static deformities of the capitate, lunate and scaphoid cause degenerative changes to the articular cartilage and joint surfaces. SLAC presents in three stages:

**Stage I:** arthritic change of the radial styloid

**Stage II:** arthritic change of the scaphoid facet of the distal radius

**Stage III:** arthritis of the articulation between the capitate and the lunate

(Caggiano & Matullo, 2014)

## Classifications: TFCC

The Mayo Clinic System of classification of TFCC tears is divided into traumatic tears and degenerative tears.

### Traumatic tears:

- I.** radial rim detachment
- II.** central tears
- III.** ulnar tears
- IV.** palmar tears

(Van Rooyen, 2005).

## Classifications: TFCC

The Mayo Clinic System of classification of TFCC tears is divided into traumatic tears and degenerative tears.

### Degenerative tears:

- I.** central tears
- II.** central tear with ulnocarpal impingement
- III.** central tear, impingement, and lunotriquetral ligament tear
- IV.** central tear, impingement, and lunotriquetral arthritis

(Van Rooyen, 2005).

## Diagnosis

**A diagnosis of wrist instability should be based upon a clinical examination, a report of the mechanism of injury, the patient's medical history and symptoms, and the results of provocative stress testing, at the minimum. Plain films should be included; however, supportive findings may not be evident, and additional tests may be ordered as results of the clinical examination and findings indicate (Cooney et al., 1990).**

## Diagnosis: Clinical Tests

- **General Midcarpal tests**
  - Midcarpal shift test
- **Scapholunate, Second and Third Carpometacarpal Joints, and Capitulate tests**
  - Scaphoid stress test (scaphoid shift test, Watson's test, SST, modified scaphoid shear test)
  - Wrist-flexion finger-extension maneuver
  - Synovial irritation sign of the scaphoid
  - Linscheid test
  - Dorsal capitate-displacement test



## Diagnosis: Clinical Tests

### •Lunotriquetral tests

- Lunotriquetral (LT) ballottement test (Reagan's test)
- Kleinman's Shear Test
- Ulnar snuffbox compression test (Linscheid's Test, lunotriquetral compression test)

### •Distal Radioulnar Joint and Triangular Fibrocartilage Complex tests

- Piano-key test
- Ulnomeniscotriquetral (UMT) dorsal glide test for pathology of the TFCC

## General Mid-carpal Tests: Mid-carpal Shift Test

"The mid-carpal shift test was described by Feinstein et al (1999) as a valid and useful clinical diagnostic test for indicating mid-carpal non-dissociative carpal instability... The test was reviewed under video-fluoroscopy, showing that the proximal carpal row maintained a flexed volar position rather than moving smoothly from flexion to extension as the wrist was moved into ulnar deviation. Instead, the proximal row suddenly snapped into extension once the ulnar deviation was achieved, hence the 'clunk' (Lichtman & Wroten, 2006)" (Pong, 2011, p. 381).

### General Mid-carpal Tests: Mid-carpal Shift Test

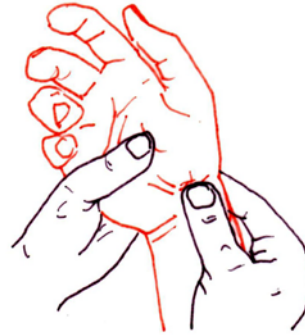
“The examiner stabilizes the patient’s forearm in pronation with one hand. With the other hand, the examiner places a thumb over the patient’s dorsal distal capitate. The thumb directs a palmar force via the capitate, allowing translation to occur. Maintaining this pressure, the examiner provides passive ulnar deviation to the patient’s wrist. A positive test consists of a degree of clunking and/or laxity during the ulnar deviation” (Pong, 2011, p. 381).

### Scapholunate Tests: Watson’s Test

“The scaphoid stress test (scaphoid shift test, Watson’s test, SST, modified scaphoid shear test) is the most commonly used clinical test for detection of scapholunate instability (Christodoulou & Bainbridge, 1999). Rodner and Weiss (2008) noted that the test may not be performed as well initially due to swelling and pain” (Pong, 2011, p. 382).

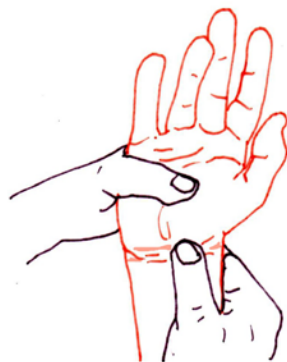## Scapholunate Tests: Watson's Test

"The examiner places a thumb on the scaphoid tubercle, applying pressure volar to dorsal, and passively moves the patient's wrist from ulnar deviation and slight extension into radial deviation with slight flexion " (Pong, 2011, p. 382).



Adapted from: (Caggiano & Matullo, 2014)

## Scapholunate Tests: Watson's Test



"The scaphoid will become prominent under the examiner's thumb with the movement to radial deviation. When the thumb pressure is removed, a positive test will demonstrate the scaphoid returning to position with an often painful and palpable 'clunk' " (Pong, 2011, p. 382).

Adapted from: (Caggiano & Matullo, 2014)

### Scapholunate Tests: Watson's Test

"The clunk is thought to occur when, due to laxity or pathology, the proximal pole of the scaphoid shifts onto the dorsal rim of the radius with thumb pressure; then it returns with a clunk when the pressure is removed (Skirven, 1996). The test is also meaningful when it reproduces pain over the scapholunate interval (Rodner & Weiss, 2008). According to LaStayo and Howell (1995), this test has sensitivity of 69%, specificity of 66%, a positive predictive value of 48% and a negative predictive value of 78% relative to arthroscopic findings in 50 painful wrists" (Pong, 2011, p. 382).

### Scapholunate Tests: Wrist-flexion Finger-Extension Maneuver

"Watson described the wrist-flexion finger-extension maneuver as an additional test of scapholunate instability (Skirven, 1996). Truong et al (1994) included this test in their screening criteria that in combination had a sensitivity of 88.5% and a specificity of 84%. The patient's wrist is positioned in flexion while the examiner applies resistance against finger extension, causing pain in the scapholunate region with a positive test (Truong et al, 1994)" (Pong, 2011, p. 382).

### Scaphoid Tests: Synovial Irritation Sign

“The synovial irritation sign of the scaphoid has high sensitivity but low specificity for detecting scaphoid instability. Van Buul et al (1993) found that a positive synovial irritation sign test had significantly higher incidence in patients with suspected carpal instability. A positive test consists of pain elicited by the examiner providing pressure on the scaphoid through the anatomical snuffbox (Van Buul et al., 1993)” (Pong, 2011, p. 382).

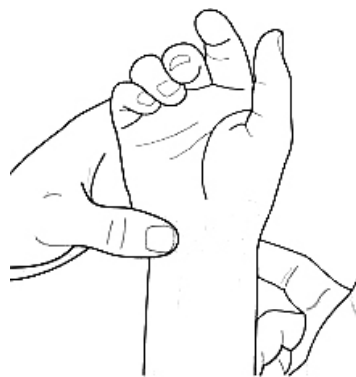### Radial Wrist Tests: Linscheid Test

“...the Linscheid test produces pain in the second and third carpo-metacarpal joints when positive (Skirven, 1996). The examiner supports the patient’s metacarpal shafts while pressing into the distal metacarpal heads in both dorsal and volar directions (Skirven, 1996)” (Pong, 2011, p. 382).

## Capitolunate and Radiolunate Tests: Dorsal Capitate-Displacement Test

“The dorsal capitate-displacement test was found to clinically successfully reproduce dorsal sub-luxation of the capitolunate or the capitolunate and radiolunate joints (Lichtman & Wroten, 2006)... The examiner applied pressure to the scaphoid tuberosity in a dorsal direction while simultaneously performing longitudinal traction and passive flexion to the patient’s wrist. This produced nearly complete dorsal sub-luxation of the capitate from the lunate and reproduced the patient’s pain in that area (Louis et al., 1984)” (Pong, 2011, p. 382).

## Lunotriquetral Tests: Reagan’s Test



*NOTE: Examiner's thumb on lunate is not shown.*

Adapted from: (Pong, 2011)

“The test is performed with the examiner using the thumb and index finger of one hand to hold the patient’s lunate while holding the triquetrum in the contralateral hand and providing simultaneous movement of these bones against one another (Dobbs, 2003)... A positive result is reproduction of pain, crepitus, or excessive laxity” (Pong, 2011, p. 382).

## Lunotriquetral Tests: Kleinman's Shear Test

"Kleinman's Shear Test is one of three clinical tests that have been reported as specific to lunotriquetral injury (Dobbs, 2003). The examiner places several fingers dorsal to the patient's lunate with a thumb on the patient's pisotriquetral joint (Skirven, 1996). Other authors have described the use of the examiner's thumb on the lunate with the contralateral thumb on the pisotriquetral joint (Dobbs, 2003). While the lunate is stabilized, the thumb provides a volar to dorsal direction of force that creates a shear across the lunotriquetral joint. The examiner then deviates the wrist first in ulnar then radial directions. Pain or clicking demonstrates a positive test (Skirven, 1996)" (Pong, 2011, p. 383).

## Lunotriquetral Tests: Ulnar Snuffbox Compression Test

"Dobbs (2003) described the ulnar snuffbox compression test (Linscheid's Test, lunotriquetral compression test) as poorly specific for lunotriquetral instability. The test is positive with pain reproduction as the examiner pushes the patient's triquetrum into the lunate from the ulnar wrist, specifically in the sulcus, or snuffbox, formed by the extensor carpi ulnaris and flexor carpi ulnaris tendons (Skirven, 1996; Rodner & Weiss, 2008)" (Pong, 2011, p. 383).

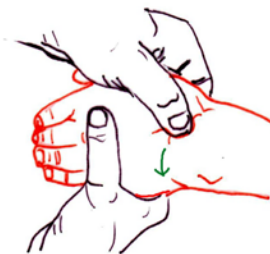


Image by Author

### DRUJ Tests: Piano Key Test

“The piano-key test is a variation of the piano-key sign, and is used to assess for distal radio-ulnar joint (DRUJ) instability. The examiner stabilizes the radius with one hand while the other hand grasps the patient’s distal ulna and moves it in dorsal and volar directions with the forearm positioned in various degrees of pronation and supination. A positive test includes reproduction of pain, tenderness, and hyper-mobility compared to the uninvolved side (Skirven, 1996)” (Pong, 2011, p. 383).

### TFCC Tests: Ulnomeniscotriquetral (UMT) Dorsal Glide Test

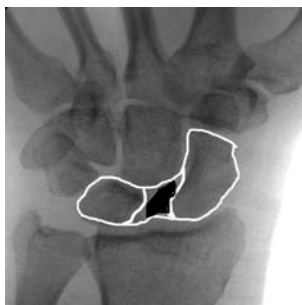“LaStayo and Howell (1995) examined the ulnomeniscotriquetral (UMT) dorsal glide test for pathology of the TFCC... A positive test results in reproduction of the patient’s pain and/or laxity in the UMT area (Hertling & Kessler, 1996). LaStayo and Howell (1995) reported sensitivity of 66%, specificity of 64%, positive predictive value of 58%, and negative predictive value of 69% for this test” (Pong, 2011, p. 383).



### TFCC Tests: Ulnomeniscotriquetral (UMT) Dorsal Glide Test

“The technique for this test has the patient’s elbow resting on a table with forearm in neutral and vertical position. The patient’s distal radius is stabilized by a golfer’s grip of the examiner’s hand. With the other hand, the examiner places his index finger (digit 2) curled such that the radial side of the proximal interphalangeal joint contacts the patient’s volar piso-triquetral complex. With this finger providing dorsal pressure, the examiner simultaneously uses the thumb to apply volar pressure against the dorsal distal ulna, producing a dorsal glide of the piso-triquetral complex on the distal ulnar head” (Pong, 2011, p. 383).

### Radiological Tests and Others



Adapted from:  
(Caggiano & Matulla, 2014)

Radiographic examination of the wrist in both standard static views and special dynamic positions and loading conditions are examined to reveal the gap between dissociated bones in wrist instability. One example is the Terry-Thomas Sign (widening of the space between the scaphoid and the lunate of greater than 2 mm) (Caggiano & Matullo, 2014; Garcia-Elias, 2006).

## Radiological Tests and Others

Video-fluoroscopy and arthrogram may demonstrate greater detail. And dynamic ultrasound may confirm midcarpal instability with a triquetral catch-up clunk (Toms et al., 2009). Although most invasive, arthroscopy is the gold standard to reveal occult differences in ligament appearance (Caggiano & Matullo, 2014; Cooney et al., 1990).

## Conservative Treatment

The literature has described conservative treatment for wrist instability as consisting of patient education, splinting, and exercises (Hofmeister et al., 2006; Lichtman & Wroten, 2006; Prosser et al., 2007). It is an understatement to say that additional research is needed to determine true efficacy of conservative treatment for wrist instability. Most reports do not specify how the patient is educated or which exercises may be helpful.

## Conservative Treatment: Patient Education

Although specific guidance has not been provided in the literature, this author's personal experience with mid-carpal instability has provided specific methods to avoid increasing the instability and pain while performing daily tasks:

1. Avoid pushing up (bearing weight) on the flat hand with extended wrist. Use either a different assist or, if unavoidable, push up on the flat end of a fist with the wrist in slight extension.

(continued)

## Conservative Treatment: Patient Education

2. Do not allow bags/purses etc. to dangle by the handles from a hook grasp with the wrist in neutral and the arm hanging and straight. Flex the elbow slightly and extend the wrist slightly to avoid traction on the ligaments engendered in the previous position.
3. When performing heavy tasks involving lifting with the forearm supinated, do not allow the wrist to extend with the load.
4. Avoid loaded wrist flexion with the hand in a fist (as in pulling on a rope or band).

## Conservative Treatment: Other

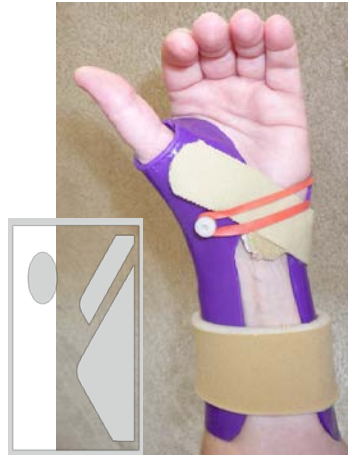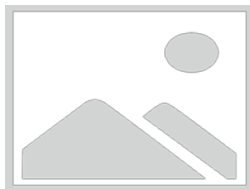Other conservative treatment modalities including immobilization, splinting, non-steroidal medications, taping and intra-articular injections have been shown to provide only temporary relief at best. To date, conservative treatment has not been shown to be restorative (Hofmeister et al., 2006; Weiss et al., 2000).

## Conservative Treatment: Splinting

Most custom and pre-fabricated splinting applications have consisted of general immobilization after acute injury such as sprain or dislocation (Coppard & Lohman, 2001). However, two unique custom splint designs have more recently shown promise in limited and specific applications (Braidotti, Atzei & Fairplay, 2015; Pong, 2011).

## Conservative Treatment: DISI Splint

Lichtman and Wroten (2006) supported use of a custom dorsal splint with a dynamic component, termed *DISI splint* or *Lichtman splint* specifically for dorsal midcarpal instability.



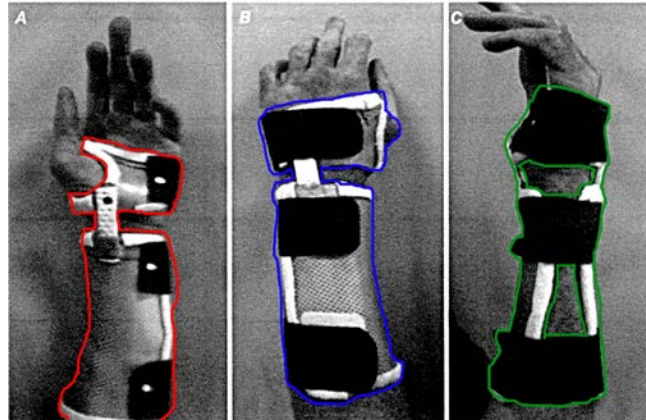
Images by Author

## Conservative Treatment: Dart Splint

The Dart-Splint was designed to be used for specific rehabilitation protocols for the purpose of limiting radiocarpal joint mobility and SLL overload. This would theoretically facilitate protected midcarpal motion and allow healing of injured or repaired tissues around the proximal carpal row (PCR), which should not be disturbed during early oblique plane wrist movements (Braidotti, Atzei & Fairplay, 2015).

## Conservative Treatment: Dart Splint

The Dart-Splint Adapted from: (Braidotti, Atzei & Fairplay, 2015)



## Invasive Treatment: Surgery

Considerations that determine course of treatment include: arthritic changes, injury onset (chronicity), probability of the tissues, based on quality, to withstand surgical repair; and the ability of the surgeon to reduce the deformity. A patient with an acute injury with reducible deformity and tissues of good quality would have the best chance for regaining function after surgery (Carlsen & Shin, 2008).

## Invasive Treatment: Surgery

Kirshner wire (K-wire), bone-ligament-bone graft, partial carpal fusion or arthrodesis, mid-carpal or four corner fusion, and proximal row carpectomy are possible choices for surgery (Garcia-Elias, 2006). Arthroscopic or open debridement including ligament and synovectomy, capsulodesis, and ligament repair or reconstruction; also anterior and posterior interosseous neurectomy are additional surgical options (Hofmeister et al., 2006; Johnston et al., 2009). Prognosis will depend upon the factors of cause, specific pathology, technique and skill of the surgeon, and ability of the patient to heal and to follow post-operative protocols.

## Summary

While there are still no magical restorative conservative treatments proven efficacious for wrist instability, adding to our knowledge base of anatomy and biomechanics of the wrist, as well as classifications of various wrist instabilities and clinical assessment techniques, may allow early and accurate identification of this pathology. As the most promising splinting applications are extremely specific, our knowledge of wrist instability must be equally as specific to explore these and other evidence-based treatments for the benefit of our patients with this condition.

## Learner Outcomes

**As a result of this course, participants will be able to:**

- 1) ...identify the bony anatomy and major ligamentous structures that are relevant to wrist instability.
- 2) ...recognize three basic patterns of wrist instability, terms that identify carpal alignment on films; and the Mayo Clinic system of carpal instability classification groups.
- 3) ... incorporate evidence-based clinical assessments for wrist instabilities into their clinical practice.
- 4) ...discuss current knowledge in conservative treatments for wrist instability, state the potentials and limitations of these treatments, and confidently explore novel custom splinting for this pathology in their clinical practice.

## References

- Bednar, J. M. & Ostermann, A. L. (1993). Carpal instability: Evaluation and treatment. *Journal of the American Academy of Orthopaedic Surgeons*, 1, 10-17.
- Bozentka, D. J. (1999). Scapholunate instability. *The University of Pennsylvania Orthopaedic Journal*, 12, 27-32.
- Braidotti, F., Atzei, A. & Fairplay, T. (2015). Dart-Splint: An innovative orthosis that can be integrated into a scapho-lunate and palmar midcarpal instability re-education protocol. *Journal of Hand Therapy*, 28, 329-335.
- Caggiano, N. & Matullo, K. S. (2014). Carpal instability of the wrist. *Orthop Clin N Am*, 45, 129-140.
- Carlsen, B. T. & Shin, A. Y. (2008). Wrist instability. *Scandinavian Journal of Surgery*, 97, 324-332.
- Chong, C. & Kandathil, J. C. (2013). MR imaging of TFCC, what every radiologist need to know. Poster ECR 2013 / C-1841. Retrieved from [http://postereng.netkey.at/esr/viewing/index.php?module=viewing\\_poster&pi=117720](http://postereng.netkey.at/esr/viewing/index.php?module=viewing_poster&pi=117720)
- Cooney, W. P., Dobyns, J. H. & Linscheid, R. L. (1990). Arthroscopy of the wrist: Anatomy and classification of carpal instability. *Arthroscopy: The Journal of Arthroscopic and Related Surgery*, 6, 133-140.



## References

- Coppard, B. M. & Lohman, H. (2001). *Introduction to Splinting. A Clinical-Reasoning and Problem-Solving Approach* (2<sup>nd</sup> ed). St. Louis, Mosby, pp. 139-241.
- De Filippo, M., Sudberry, J. J., Lombardo, E. et al. (2006). Pathogenesis and evolution of carpal instability: imaging and topography. *Acta bio-medica : Atenei Parmensis*, 77, 168-180.
- Dobbs, A. (2003). The ulnar side of the wrist. *The North American Institute of Orthopaedic Manual Therapy*, 8, 1-5.
- Dumontier, C. (1996). Physical examination of wrist instabilities. *Maitrise Orthopedique*, 49. Online Orthopedic Journal. Retrieved from [http://www.maitrise-orthop.com/viewPage\\_us.do?id=153](http://www.maitrise-orthop.com/viewPage_us.do?id=153)
- Garcia-Elias, M. (1997a). The treatment of wrist instability. *Journal of Bone and Joint Surgery* 79-B(4), 684-690.
- Garcia-Elias, M. (1997b). Kinetic analysis of carpal stability during grip. *Hand Clinics*, 13, 151-158.
- Garcia-Elias, M. (2006). Treatment of scapholunate instability. *Ortopedia Traumatologia Rehabilitacja*, 2, 160-168.
- Hofmeister, E. P., Moran, S. L. & Shin, A. Y. (2006). Anterior and posterior interosseous neurectomy for the treatment of chronic dynamic instability of the wrist. *Hand*, 1, 63-70.

## References

- Johnston, K., Durand, D., Hildebrand, K. A. et al. (2009). Chronic volar distal radioulnar joint instability: joint capsular placcation to restore function. *Canadian Journal of Surgery*, 52, 112-118.
- Kitay, A. & Wolfe, S. W. (2012). Scapholunate instability: current concepts in diagnosis and management. *J Hand Surg*, 37A, 2175-2196.
- Kleinman, W. B. (2007). Stability of the distal radioulnar joint: biomechanics, pathophysiology, physical diagnosis, and restoration of function what we have learned in 25 years. *Journal of Hand Surgery*, 32A, 1086-1106.
- Lichtman, D. M. & Wroten, E. S. (2006). Understanding midcarpal instability. *Journal of Hand Surgery*, 31A, 491-498.
- Lieber, R. L. & Friden, J. (1998). Musculoskeletal balance of the human wrist elucidated using intraoperative laser diffraction. *Journal of Electromyography and Kinesiology*, 8, 93-100.
- Linscheid, R. L. & Dobyns, J. H. (2002). Dynamic carpal stability. *Keio Journal of Medicine*, 51, 140-147.
- Ozcelik, A., Gunal, I., Kose, N. et al. (2005). Wrist ligaments: their significance in carpal instability. *Turkish Journal of Trauma and Emergency Surgery*, 11, 115-120.

## References

- Pong, E. (2011). Wrist Instability. In C. Fernández-de-las-Peñas, J. A. Cleland, & P. Huijbregts (Eds.), *Neck and Arm Pain Syndromes: Evidence-Informed Screening, Diagnosis, and Management in Manual Therapy*. (chap. 27). Edinburgh, UK: Elsevier.
- Prosser, R., Herbert, R. & LaStayo, P. C. (2007). Current practice in the diagnosis and treatment of carpal instability – results of a survey of Australian hand therapists. *Journal of Hand Therapy*, 20, 239-242.
- Schmitt, R., Froehner, S., Coblenz, G. et al. (2006). Carpal instability. *European Radiology*, 16, 2161–2178.
- Shin, A. Y., Battaglia, M. J. & Bishop, A. T. (2000). Lunotriquetral instability: Diagnosis and treatment. *Journal of the American Academy of Orthopaedic Surgeons*, 8, 170-179.
- Toms, A., Chojnowski, A. & Cahir, J. (2009). Midcarpal instability: A diagnostic role for dynamic ultrasound? *Ultraschall in der Medizin*, 30, 286-290.
- Van Rooyen, C. (2005). Radiologic evaluation of the hand and wrist. In: McKinnis LN (ed) *Fundamentals of Musculoskeletal Imaging*, (2<sup>nd</sup> Ed). FA Davis, Philadelphia, p. 509-521.
- Wadsworth, C. (1988). *The Wrist and Hand in Manual Examination and Treatment of the Spine and Extremities*. Williams & Wilkins (January 15, 1988).
- Weiss, L. E., Taras, J. S., Sweet, S. et al. (2000). Lunotriquetral injuries in the athlete. *Hand Clinics*, 16, 433-438.

## Questions and Answers:

### Point of Contact:

Please feel free to email me with any additional questions or discussion of this course. Thank you for your time and attention!

[ejpong@bellsouth.net](mailto:ejpong@bellsouth.net)