

If you are viewing this course as a recorded course after the live webinar, you can use the scroll bar at the bottom of the player window to pause and navigate the course.

This handout is for reference only. It may not include content identical to the powerpoint.

Any links included in the handout are current at the time of the live webinar, but are subject to change and may not be current at a later date.

Management of Adhesive Capsulitis

David Nolan, PT, DPT, MS, OCS, SCS, CSCS

Learning Objectives

4

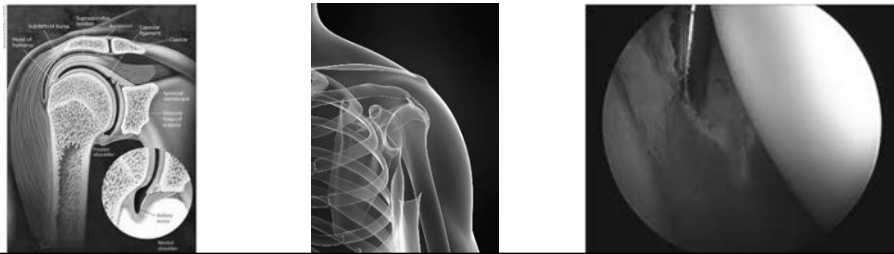
- Describe at least 3 anatomical and at least 3 pathophysiological changes that occur with adhesive capsulitis.
- List at least three of the associated stages of adhesive capsulitis and the signs and symptoms of each stage.
- Outline the clinical presentation of adhesive capsulitis and associated differential diagnosis considerations.
- List at least 5 treatment strategies based on patient classification and irritability level.
- Develop an evidence-based treatment program for patients with adhesive capsulitis.

Frozen Shoulder

5

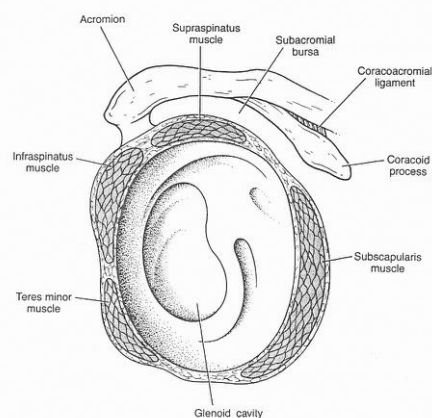
“A condition difficult to define, difficult to treat, and difficult to explain from the point of view of pathology.”
(Codman)

Often used to refer to any shoulder condition consisting of pain and limited ROM



Clinical Controversy

6



- Adhesive capsulitis vs. stiff painful shoulder
 - Are they the same thing?
 - Is the treatment approach different?
 - Is aggressive treatment the most successful?
 - Referred to as “Self-Limiting” condition

Clinical Controversy

7

- Some literature has shown recovery of severe cases without treatment in 2 years
- Other studies have shown patients to remain symptomatic for 3-10 years

Is It Self-Limiting?

8

- Grey RG. *JBJS* 1978
 - Simple analgesics & reassurance (2 yr F/U)
 - 24/25 “absolutely normal function”
- Miller MD. et al. *Orthopedics* 1996
 - 50 patients treated with moist heat & NSAIDs
 - 100% reported normal function of arm & minimal residual arm pain (4 yr F/U)
- Griggs *JBJS* 2000
 - Prospective study of 75 patients with adhesive capsulitis
 - 90% successful with “stretching” program
 - ROM improved
 - Flexion ↑by 43°
 - ER ↑by 25°

Is It Self-Limiting?

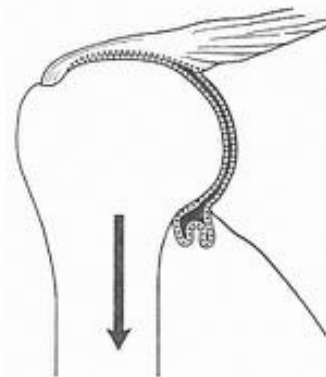
9

- Shaffer et al. *JBJS* 1992
 - **62 patients with adhesive capsulitis**
 - **Interventions included**
 - PT, NSAIDs, Injections, MUA
 - **7 year follow-up**
 - 50% had mild pain and stiffness
 - 60% had restricted motion
 - Only 40% demonstrated symmetrical motion
- Hand C. et al. *JSES* 2008
 - **50% had residual mild pain and decreased motion**
- Studies with patient based outcomes seem to be more favorable than those utilizing objective data

Adhesive Capsulitis Definition

10

- An inflammatory reaction of the capsule &/or synovium that subsequently leads to formation of adhesions in the axillary fold and attachment of inferior capsule to anatomic neck
- Neviaser; *JBJS* 1945



Adhesive Capsulitis Definition

11

- Zuckerman JD & Rokito A. *JSES* 2011
 - **Frozen shoulder is a condition characterized by functional restriction of both active and passive shoulder motion for which radiographs of the glenohumeral joint are essentially unremarkable except for the possible presence of osteopenia or calcific tendinitis**

Adhesive Capsulitis Definition

12

- Zuckerman JD & Rokito A. *JSES* 2011
 - **Classification**
 - Primary
 - Primary frozen shoulder is considered a diagnosis for all cases for which an underlying etiology or associated condition cannot be identified
 - Secondary
 - The secondary types of frozen shoulder include all cases of frozen shoulder in which an underlying etiology or associated condition can be identified

Adhesive Capsulitis Definition

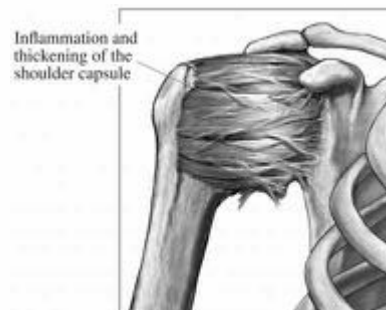
13

- Zuckerman JD & Rokito A. *JSES* 2011
 - **Secondary Frozen Shoulder**
 - Intrinsic
 - Occurs in association with rotator cuff disorders, biceps tendinitis or calcific tendinitis
 - Extrinsic
 - Association with an identifiable abnormality remote to the shoulder itself. I.E. breast surgery, cervical radiculopathy, CVA, MI, humeral fracture, AC arthritis
 - Systemic
 - Association with systemic disorders such as DM, hyper/hypothyroidism, hypoadrenalism

Frozen Shoulder: Clinical

14

- Cyriax
 - **Freezing: 1-6 months**
 - Acute
 - Vague lateral arm pain
 - **Frozen: 6-12 months**
 - Little to no pain
 - Significant motion loss
 - Capsular Pattern
 - ER > ABD > IR-Flexion
 - **Thawing: 12-24 months**
 - Resolution of impairments



Frozen Shoulder: Arthroscopic

15

- Stage 1 / Pre-Adhesive Stage
 - Duration of symptoms: 0 to 3 months
 - Synovial inflammation
 - No capsular changes present
 - Minimal or no limitation in mobility
 - Pain with A-PROM at end range
 - Deltoid region
 - Similar to impingement or tendinitis
 - Clinical Pearl
 - Misdiagnosed with RC impingement
 - Limited ER with intact RC strength

Kelley MJ et al. Shoulder Pain and Mobility Deficits: Adhesive Capsulitis. *J Orthop Sports Phys Ther.* 2013;43(5):A1-A31.

Neviaser AS, Hannafin JA. Adhesive Capsulitis A Review of Current Treatment. *Am J Sports Med.* 2010;38(11):2346-2356.

Neviaser T.J. Adhesive Capsulitis: Management of Shoulder Problems. *Orthop Clin North Am.* 1987;18:439-443

Frozen Shoulder: Arthroscopic

16

- Stage 2 / Acute Adhesive Stage / Freezing Stage
 - Duration of symptoms: 3 to 9 months
 - Synovitis (red) and early capsular adhesions
 - Progressive shoulder pain with A-PROM
 - Loss of joint space
 - Limited mobility in all planes



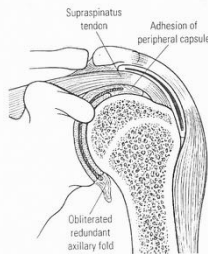
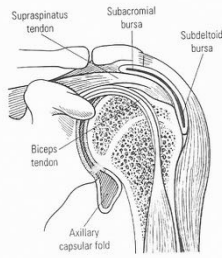
Kelley MJ et al. Shoulder Pain and Mobility Deficits: Adhesive Capsulitis. *J Orthop Sports Phys Ther.* 2013;43(5):A1-A31.

Neviaser AS, Hannafin JA. Adhesive Capsulitis A Review of Current Treatment. *Am J Sports Med.* 2010;38(11):2346-2356.

Neviaser T.J. Adhesive Capsulitis: Management of Shoulder Problems. *Orthop Clin North Am.* 1987;18:439-443

Frozen Shoulder: Arthroscopic

17



• Stage 3 / Fibrotic Stage / Frozen Stage

- **Duration of symptoms: 9 - 15 months**
- **Primary C/O stiffness**
- **Loss of axillary fold and decreased synovitis (pink)**
 - ? Able to sleep through night
- **Limitation in movement with rigid end-feel**
 - Unchanged with intra-articular injection
- **Pain at end-range & at night**

Kelley MJ et al. Shoulder Pain and Mobility Deficits: Adhesive Capsulitis. *J Orthop Sports Phys Ther.* 2013;43(5):A1-A31.

Neviaser AS, Hannafin JA. Adhesive Capsulitis A Review of Current Treatment. *Am J Sports Med.* 2010;38(11):2346-2356.

Neviaser TJ. Adhesive Capsulitis: Management of Shoulder Problems. *Orthop Clin North Am.* 1987;18:439-443

Frozen Shoulder: Arthroscopic

18

• Stage 4 / Chronic Adhesive Stage / Thawing Phase

- **Duration of symptoms: 15 to 24 months since onset**
- **Minimal pain / No synovitis present**
- **Arthroscopy**
 - Mature adhesions and significant restrictions
- **Resolution of symptoms?**
- **Critical to understand that the stages are not distinct but rather represent a continuum of disease**

Kelley MJ et al. Shoulder Pain and Mobility Deficits: Adhesive Capsulitis. *J Orthop Sports Phys Ther.* 2013;43(5):A1-A31.

Neviaser AS, Hannafin JA. Adhesive Capsulitis A Review of Current Treatment. *Am J Sports Med.* 2010;38(11):2346-2356.

Neviaser TJ. Adhesive Capsulitis: Management of Shoulder Problems. *Orthop Clin North Am.* 1987;18:439-443

Risk Factors

19

Adhesive Capsulitis

A Review of Current Treatment

Andrew S. Neviaser, MD, and Jo A. Hannafin,* MD, PhD
From the Hospital for Special Surgery, New York City, New York

- Insidious onset
- 2%-5% of all shoulder conditions
- Women > Men
- 40-65 years old
- Non-dominant vs. Dominant conflicting
- Sedentary workers
- Hemiplegic shoulder
- Rheumatoid Arthritis
- Cardiac disease
 - **Elevated serum lipid levels (Bunker et al.)**
- Hypothyroidism
- Diabetes Mellitus

Risk Factors

20

- Diabetes Mellitus
 - **Incidence = 10-20% and often bilateral (Placzek et al. *Clin Orthop*, 1998)**
 - **Ogilvie-Harris et al. *Arthroscopy* 1997**
 - Hyperglycemia leads to increase in intermolecular cross-linkages in collagen
 - Collagen is more resistant to degeneration and more likely to accumulate
 - Collagen cross-links may also increase the stiffness of connective tissue

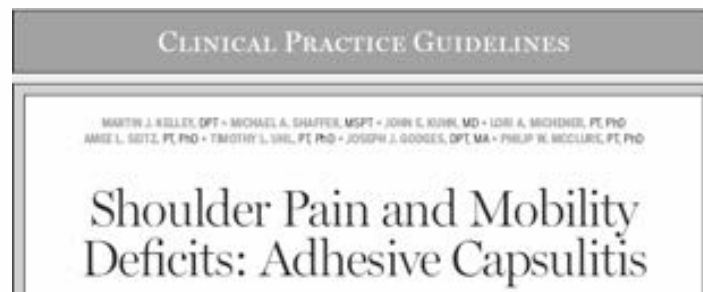
Prevalence

21

- Milgrom et al. *Isr Med Assoc J.* 2008
 - **126 patients with idiopathic adhesive capsulitis**
 - 29.3% had DM
 - **76 women (55 yo \pm 8.4) & 50 men (54.7 yo \pm 8.7)**
 - Women with DM = 23.7% vs. 4.7%
 - Men with DM = 38% vs. 6.5%
 - **Hypothyroidism**
 - 21.1% with idiopathic adhesive capsulitis vs. 7.9% age-matched control
 - Predominantly females

Pathology

22

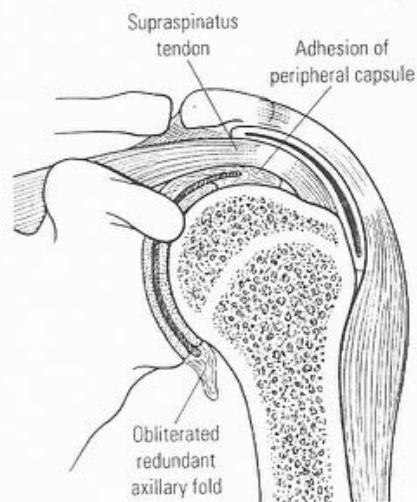


- Elevated serum cytokine levels
 - **Synovial inflammation**
 - \uparrow Pain & limited motion
 - **GHJ capsuloligamentous complex fibrotic**
 - Contracture & \downarrow ROM
 - **New nerve growth in capsuloligamentous complex**
 - \uparrow pain

Pathology

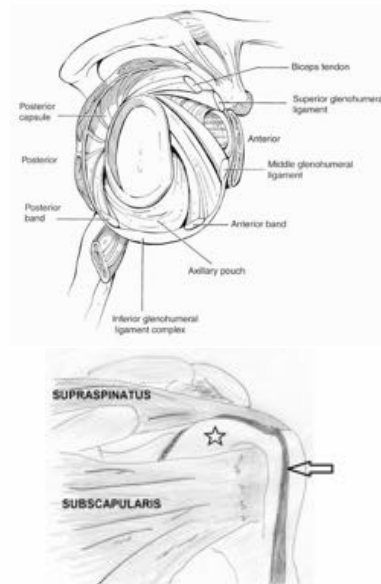
23

- Chronic capsular inflammation
- Capsular fibrosis
- Constrictive capsulitis
- Adhesion of synovial folds
- Obliteration of joint cavity
- Formation of scar tissue
- Thickened and contracted capsule becomes fixed to bone



Pathomechanics of Motion Loss 24

- Contractures
 - **Capsule**
 - **Ligaments**
 - **Muscultendinous units**
- Adhesions
 - **Rotator Cuff Interval**
 - Roubal et al *JOSPT* 1996
 - **Biceps & Subscapularis**
 - Fareed et al *Clin Orthop* 1989
- Scapulothoracic Restrictions
- Pain produces guarding and RC inhibition



Diagnostic Criteria

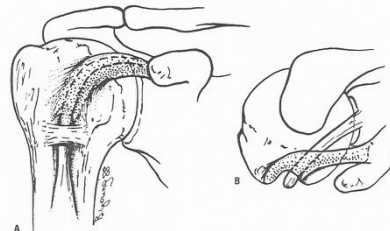
25

- Recognition of capsular pattern (Cyriax)
 - **ER > ABD > IR**
 - **Conflicting evidence**
- Zuckerman et al *JSES*, 1994
 - **Insidious onset, night pain**
 - **Painful and limited A-PROM**
 - Elevation <100°
 - ER <50% of normal at 0° Abd
 - **Normal radiographs**
- JOSPT Clinical Practice Guidelines 2013
 - **Loss of AROM & PROM**
 - **ROM loss >25% in 2+ planes**
 - **Passive ER loss >50% of uninvolved or <30°**
- Key = **ALL** motions limited

Patient Presentation

26

- Insidious onset
- Pain predominant early
 - **New nerve growth in capsuloligamentous complex**
 - Hand GC et al. *JBJS (Br)* 2007
 - **Vague in deltoid area and**
 - **C5 distribution along lateral arm**
- Pain on palpation
 - **Bicipital groove**
- Difficulty sleeping
- Pain at rest subsides with progression
- Pain resolves spontaneously
- Motion restriction continues



Outcome Measures

27

- Disabilities of the Arm, Shoulder and Hand (DASH)
 - **MCID 10.2 points**
 - Roy JS et al. *Arthritis Rheum.* 2009
- QuickDASH
 - **MCID 8 points**
 - Mintken PE et al. *JSES.* 2009
- Shoulder Pain and Disability Index (SPADI)
 - **MCID 8-13 points**
 - Roy JS et al. *Arthritis Rheum.* 2009
- Penn Shoulder Scale
 - **MCID 11.4 points**
 - Leggin BG et al. *JOSPT.* 2006

Physical Exam

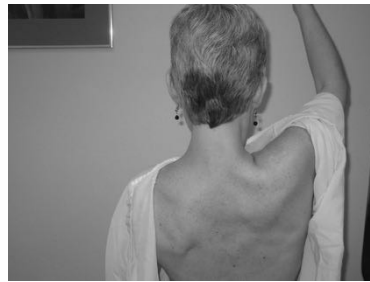28

- Acute
 - Protected limb
 - Guarded motion
 - Significant difficulty sleeping
 - Prefer to use sling
 - Muscle spasm
 - ROM difficult to assess
 - Empty end feel: Pain before end-range resistance

Physical Exam

29

- Sub-Acute / Chronic
 - **Motion restriction predominant feature**
 - **Scapular substitution**
 - Vermeulen HM et al. *Ann Rheum Dis.* 2002
 - Rundquist PJ et al. *Arch Phys Med Rehabil.* 2003
 - **Disuse atrophy of shoulder complex muscles**
 - **ROM restricted with end-range pain**
 - **MMT in mid-range asymptomatic**
 - Weak IR & elevation
 - **Capsular pattern**
 - **Limited joint play throughout**
 - Inferior is most limited then anterior



Clinical Identifiers Stage 1

30

- Walmsley S et al. *Phys Ther.* 2009
 - **Strong component of night pain**
 - **Marked increase in pain with rapid or unguarded movements**
 - **Uncomfortable to lie on affected shoulder**
 - **Pain is easily aggravated by movement**
 - **Older than 35 yo**
 - **End range pain in all directions**
 - **Global loss of A/PROM**
 - **Global loss of passive GHJ mobility**

Clinical Identifiers Stage 1

31

- Walmsley S et al. *Phys Ther.* 2014
– None of the clinical identifiers validated

Table 2.

Prevalence of the 8 Clinical Identifiers (n=64)

Criteria	No. of Participants (%)
There is a strong component of night pain	62 (96.9)
There is a marked increase in pain with rapid or unguarded movements	57 (89.1)
It is uncomfortable to lie on the affected shoulder	61 (95.3)
The patient reports the pain is easily aggravated by movement	55 (85.9)
The onset generally occurs in people older than 35 years of age	64 (100)
On examination, there is pain at the end of range in all directions	Active: 59 (92.2) Passive: 60 (93.8)
On examination, there is global loss of active and passive range of movement	Active: 42 (65.6) Passive: 43 (67.2)
There is global loss of passive glenohumeral joint movement	47 (73.4)

32

[CLINICAL COMMENTARY]

MARTIN J. KELLEY, PT, DPT, OCS¹ • PHILLIP W. MCCLURE, PT, PhD² • BRIAN G. LEGG, PT, DPT, OCS³

Frozen Shoulder: Evidence and a Proposed Model Guiding Rehabilitation

TABLE 1	IRRITABILITY CLASSIFICATION		
High Irritability	Moderate Irritability	Low Irritability	
High pain (>3/10)	Moderate pain (4-6/10)	Low pain (<3/10)	
Consistent night or resting pain	Intermittent night or resting pain	No resting or night pain	
High disability on DASH, ASES, PSS	Moderate disability on DASH, ASES, PSS	Low disability on DASH, ASES, PSS	
Pain prior to end ROM	Pain at end ROM	Minimal pain at end ROM with overpressure	
AROM less than PROM, secondary to pain	AROM similar to PROM	AROM same as PROM	
<i>Abbreviations: AAROM, active-assisted range of motion; AROM, active range of motion; ASES, American Shoulder and Elbow Surgeons Score; DASH, Disabilities of the Arm, Shoulder and Hand Questionnaire; PROM, passive range of motion; PSS, Penn Shoulder Score; ROM, range of motion.</i>			

Subjective History

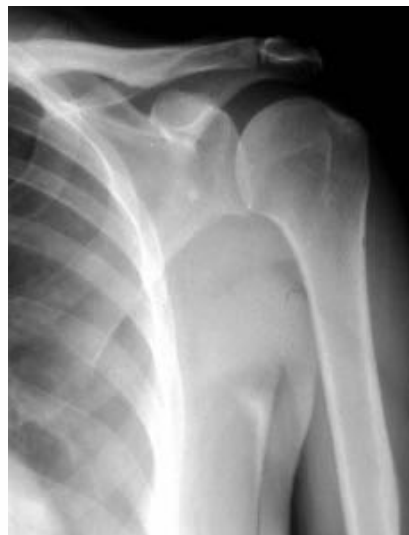33

- Ability to sleep through night
- What is the predominant symptom
 - **Pain vs. stiffness**
- Improving or worsening over the last 3 weeks

Diagnostic Imaging

34

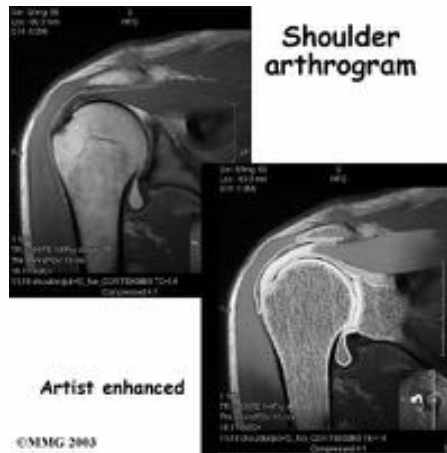
- Radiographs
 - **Typically normal**
 - **Rule-out pathology**
 - Osteoarthritis
 - Osteoporosis
 - Degenerative changes
 - Calcium deposits
 - Decreased subacromial space



Diagnostic Imaging

35

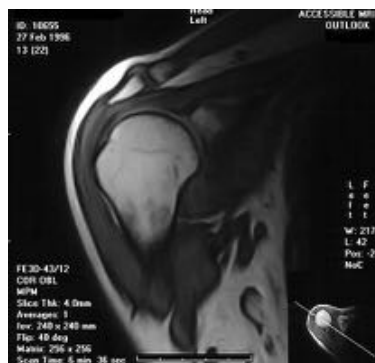- Arthrography
 - “Gold Standard”
 - 50% reduction of joint volume
 - Normal = 20-30ml dye
 - Frozen Shoulder = 5-10ml dye



Diagnostic Imaging

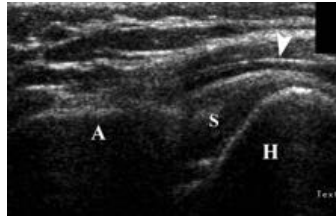
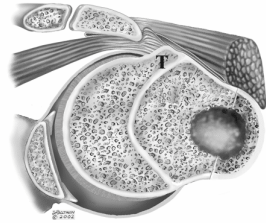
36

- MRI
 - Lee JC. et al. *Clin Radiol.* 2007
 - R/O RC & labrum
 - Identify abnormal Rotator Interval
 - Emig et al. *AJR.*1995
 - Inferior joint capsule and synovial thickening >4mm was a significant finding



Diagnostic Imaging

37



- Dynamic Sonography
 - Lee JC. et al. *Skeletal Radiol.* 2005
 - Differentiate RC tendinopathy
 - 100% (30/30) patients with frozen shoulder had fibrovascular inflammatory changes in Rotator Interval
 - Ryu et al. *J Ultrasound Med.* 1993
 - Limited gliding of supraspinatus tendon
 - Biceps muscle sheath effusion present
 - Sensitivity = 91%
 - Specificity = 100%

Differential Diagnosis

38

- Impingement Syndrome
 - Normal accessory glide at GH joint
- Rotator Cuff Lesion
 - Normal PROM and accessory glide at GH joint
 - Pain with AROM with arm at side
- Biceps Tendinitis
 - Closely related to adhesive capsulitis
 - Pain present with both diagnoses
 - Normal accessory glide at GH joint

Differential Diagnosis

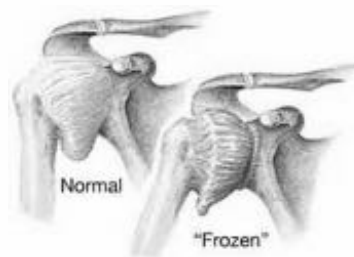
39

- Osteoarthritis
 - Pain and capsular pattern with both (Cyriax)
 - (+) Radiographic findings: spurring, ↓ joint space
- Cervical Radiculopathy
 - Similar pain in C5 distribution
 - Symptoms reproduced with cervical exam
- Neural Tension
 - Typical with trauma or repetitive stress
- Medical Complications
 - Heart, lungs, spleen, gall bladder and thyroid
 - Absence of mechanical findings

Treatment

40

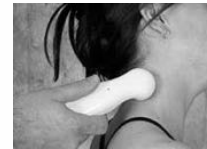- Goals
 - Decrease pain
 - Decrease inflammation
 - Education
 - Restore capsular mobility
 - Optimizing treatment depends on recognition of the clinical stage at presentation because the condition progresses through a predictable sequence
 - Neviaser AS. et al. *AJSM* 2010



Modalities

41

- Gursel YK. et al. *Phys Ther.* 2004
 - **Lack of efficacy when US compared to sham US in treating soft tissue disorders of the shoulder.**
- Jewell DV. et al. *Phys Ther.* 2009
 - **Iontophoresis, Phonophoresis, Ultrasound, or Massage reduced likelihood of improvement by 19% - 32%**



Modalities

42

CLINICAL PRACTICE GUIDELINES

MARTIN J. KELLEY, DPT • MICHAEL A. SHAFER, MSPT • JOHN E. KUHN, MD • LORI A. MICHENER, PT, PhD
AMEE L. SEITZ, PT, PhD • TIMOTHY L. UHL, PT, PhD • JOSEPH J. GOGGES, DPT, MA • PHILIP W. MCCLURE, PT, PhD

Shoulder Pain and Mobility Deficits: Adhesive Capsulitis

INTERVENTION – MODALITIES: Clinicians may utilize short-wave diathermy, ultrasound, or electrical stimulation combined with mobility and stretching exercises to reduce pain and improve shoulder ROM in patients with adhesive capsulitis. (Recommendation based on weak evidence.)

Exercise Intervention: HEP

43

- Mao et al. 1997
 - **HEP of AAROM: 30 minutes 3x/day**
 - **Significant gains with all motions**
- Holmes et al. 1997
 - **Case study showed good results using HEP and patient education**
- O’Kane et al. 1999
 - **41 patients: HEP of stretching**
 - **Significant improvement still present at 25 month F/U**
- Kivimaki J. et al. *JSES*. 2007
 - **HEP compared to MUA & HEP**
 - **No difference at F/U (6 wks, 3, 6, 12 month)**
 - Slight increase in ROM only

Exercise Intervention

44

- Miller et al. *Orthopaedics*. 1996
 - **50 patients treated with “overaggressive” PT**
 - **Program consisted of 3 phases**
 - **Patients were monitored every 8 weeks**
 - **Phase 1**
 - Rest, medication, sling use
 - **Phase 2**
 - Pendulum exercises and PROM
 - **Phase 3**
 - Stretching using wand and pulley
 - **Average time of ROM return was 14 months (3-36+)**
 - ****No Control Group****

Exercise Intervention

45

- Diercks RL. & Stevens M. *JSES*. 2004
 - **Intensive PT vs. Supervised Neglect**
 - Intensive: Exercise to and beyond pain threshold
 - Neglect: No exercise beyond pain threshold
 - **Both groups improved**
 - Constant score > 80 @ 24 month F/U
 - Intensive: 63%
 - Neglect: 89%
 - **Conclusion**
 - Aggressive stretching beyond pain threshold could be detrimental, especially in early phase of condition

Exercise Intervention

46

- Griggs et al. *JBJS*, 2000
 - **75 patients with stage 2 adhesive capsulitis**
 - **Outcome Measures:**
 - Pain, ROM, DASH, Simple Shoulder Test, SF-36
 - **PT & HEP of passive stretching**
 - Forward Flexion, ER, H-Add, IR
 - **Follow-Up at 22 months**
 - **90% had good outcomes with exercise program**
 - Forward flexion ↑ 43° ER ↑ 25°
 - IR ↑ 8 vertebral levels H-Add ↑ 72°

Exercise Intervention

47

- Levine WN et al. *JSES*. 2007
 - **Retrospective study: 98 patients (105 shoulders)**
 - **89.5% resolved with non-op treatment**
 - 17/19 diabetic shoulders resolved
 - **Mean age non-op = 56 yo; surgery = 51 yo**
 - **Treatment:**
 - NSAIDs (100%)
 - PT (89.5%)
 - PT without cortisone (52.4%)
 - PT with cortisone (37.1%)

Exercise Intervention

48

- Levine WN et al. *JSES*. 2007
 - **Tests & Measures**

	Initial Exam	Discharge	Percent Change
Elevation	118° ± 22°	164° ± 17°	39%
External Rotation	26° ± 16°	59° ± 18°	126%

- **Non-Op Treatment Duration:**
 - Successful non-op: 3.8 months ±3.6 months
 - Surgical: 12.4 months ±12.1 months

Exercise Intervention

49



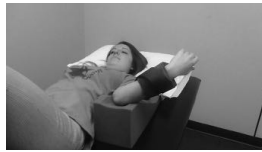Masterclass

New concepts in restoring shoulder elevation in a stiff and painful shoulder patient

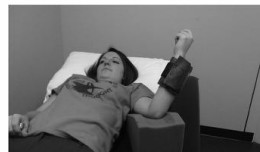

Robert Donatelli^{a,*}, R.M. Ruivo^b, Michael Thurner^c, Mahmoud Ibrahim Ibrahim^d

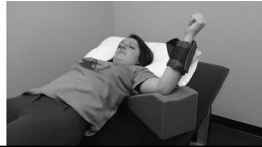0° M/L
Subscapularis



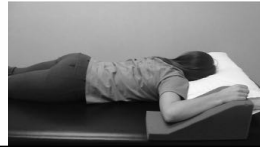30° U/M/L
Subscapularis



45° MGHL



90° IGHL



Exercise Intervention

50



Masterclass

New concepts in restoring shoulder elevation in a stiff and painful shoulder patient

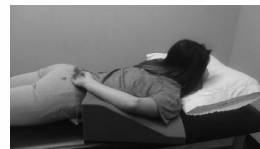

Robert Donatelli^{a,*}, R.M. Ruivo^b, Michael Thurner^c, Mahmoud Ibrahim Ibrahim^d

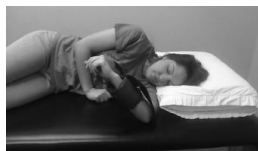30° ABD
Superior
Posterior
Capsule



30° ABD & Ext
Inferior
Posterior
Capsule

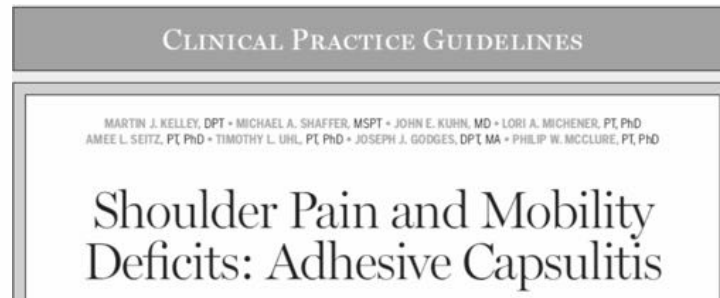


90° Flexion
Posterior Capsule



Exercise Intervention

51



INTERVENTION – STRETCHING EXERCISES: Clinicians should instruct patients with adhesive capsulitis in stretching exercises. The intensity of the exercises should be determined by the patient's tissue irritability level. (Recommendation based on moderate evidence.)

Mobilization Interventions

52

- Vermeulen HM. et al. *Phys Ther.* 2000
 - Case Series of 7 patients
 - End-range mobilization techniques only
 - Significant improvement in AROM, PROM, pain and joint volume
- Vermeulen HM. et al. *Phys Ther.* 2006
 - High-grade vs. Low-grade mobilizations
 - 24 sessions over 12 wks & followed 12 mo
 - High grade group did better but few comparisons were statistically significant
- Yang JL. et al. *Phys Ther.* 2007
 - Multiple-treatment trial using end-range, mid-range & MWM
 - End-range mobilizations & MWM more effective in increasing motion & functional mobility

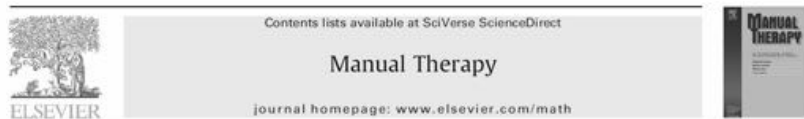Mobilization Interventions

53

- Johnson et al. JOSPT 2007
 - **20 patients with adhesive capsulitis**
 - **ER worsened with shoulder abduction**
 - Implicates capsule vs. muscle restriction
 - **Two treatment groups that received 6 sessions of US, Joint mobilization and UBE**
 - Group 1: Posterior glide (grade 3 1 min hold x15 minutes)
 - Group 2: Anterior glide (grade 3 1 min hold x 15 minutes)
 - **ER measured at initial exam and post each session**
 - **Anterior Group**
 - Mean improvement of 3°
 - **Posterior Group**
 - Mean improvement of 31.3°

Mobilization Interventions

54



Original article

Effectiveness of the end-range mobilization and scapular mobilization approach in a subgroup of subjects with frozen shoulder syndrome: A randomized control trial

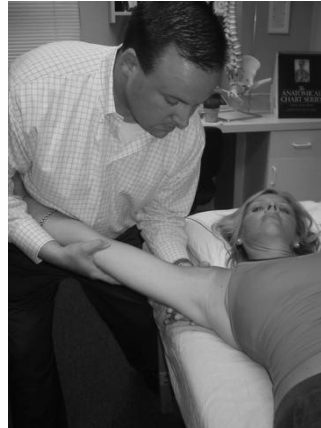Jing-lan Yang^a, Mei-Hwa Jan^b, Chein-wei Chang^a, Jiu-jenq Lin^{b,c,*}

- 34 subjects: 11 control; 23 randomized to standard PT or EMSMTA
- Rx 2x/week for 12 weeks
- 8 week F/U
 - **EMSMTA significant improvements in ROM and Disability score compared to standard PT and control**

Mobilization Interventions

55

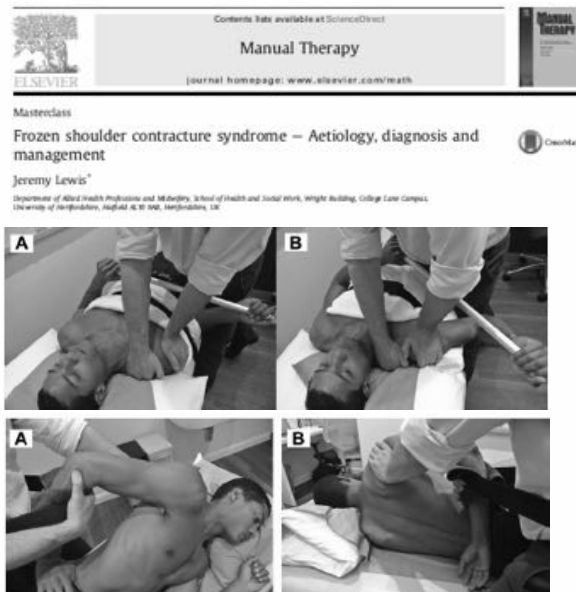
- Techniques
 - **Distraction**
 - **Anterior**
 - **Posterior**
 - **Inferior**
 - **Combined Movements**
 - Anterior-Inferior
 - Limited ER
 - Add ER to take up slack
 - Posterior-Inferior
 - Limited IR
 - Add IR to take up slack



Mobilization Interventions

56

- *Lewis J Manual Therapy 2015*
- Anterior / Posterior
- Inferior



Mobilization Interventions

57

CLINICAL PRACTICE GUIDELINES

MARTIN J. KELLEY, DPT • MICHAEL A. SHAFFER, MSPT • JOHN E. KUHN, MD • LORI A. MICHENER, PT, PhD
AMEE L. SEITZ, PT, PhD • TIMOTHY L. UHL, PT, PhD • JOSEPH J. GODGES, DPT, MA • PHILIP W. MCCLURE, PT, PhD

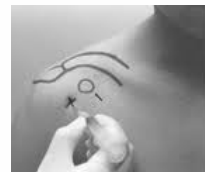Shoulder Pain and Mobility Deficits: Adhesive Capsulitis

INTERVENTION – JOINT MOBILIZATION: Clinicians may utilize joint mobilization procedures primarily directed to the glenohumeral joint to reduce pain and increase motion and function in patients with adhesive capsulitis. (Recommendation based on weak evidence.)

Corticosteroid Injection

58

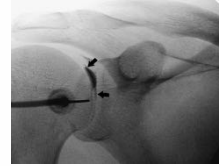
- Reduce pain and muscle guarding
 - Sheridan MA. & Hannafin JA. *Orthop Clin North Am.* 2006
- Faster initial relief of symptoms
 - van der Windt DA. et al. *BMJ.* 1998
- Improved pain and ROM in initial 4 weeks
 - Bulgen DY. et al. *Ann Rheum Dis.* 1984



Corticosteroid Injection

59

- Carette S. et al. *Arthritis Rheum.* 2003
 - **Randomized prospective study (n = 90)**
 - **Compared 4 groups**
 - Intra-articular corticosteroid injection with HEP
 - Intra-articular corticosteroid injection with HEP and PT
 - Intra-articular saline injection with PT
 - Intra-articular saline injection with HEP
 - **6 Weeks**
 - Largest change in SPADI seen in corticosteroid groups
 - **6 Months**
 - SPADI scores similar across groups
 - A/PROM better in corticosteroid-PT-HEP group
 - **12 Months**
 - No differences



Corticosteroid Injection

60

- Timing plays a role
 - **Ryans I et al. *Rheumatology* 2005**
 - 6 Weeks:
 - Intraarticular injection groups significantly improved compared to therapy groups
 - 16 Weeks:
 - All groups improved; no differences between groups
 - **Bal A et al. *Clin Rehabil.* 2008**
 - 2 Weeks:
 - Injection group showed significant improvement
 - 12 Weeks
 - Significant improvement in all groups; no differences

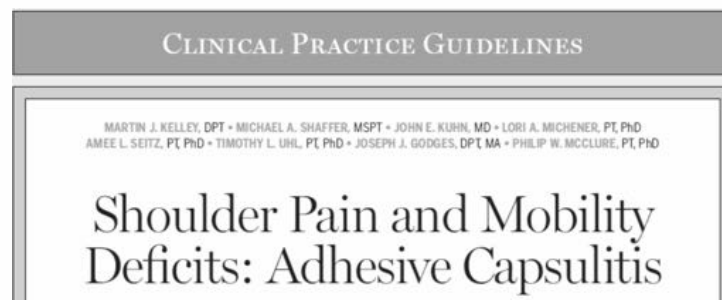
Corticosteroid Injection

61

- Walmsley S et al. *Phys Ther.* 2014
 - **Associated with (+) anesthetic response following intra-articular corticosteroid injection**
- End range pain in all directions
- Global loss of PROM
- Global loss of passive GHJ mobility

Corticosteroid Injection

62



INTERVENTION – CORTICOSTEROID INJECTIONS: Intra-articular corticosteroid injections combined with shoulder mobility and stretching exercises are more effective in providing short-term (4-6 weeks) pain relief and improved function compared to shoulder mobility and stretching exercises alone. (Recommendation based on strong evidence.)

Manipulation Under Anesthesia 63

- General anesthesia / brachial plexus block
 - **Method**
 - Short lever arm force into abduction while stabilizing scapula followed by manipulation into ER and IR
 - 75% - 100% Success rate reported in literature
 - **Complications**
 - Fractures: glenoid, scapular, humeral
 - Dislocation
 - RC / labral tear
 - Hemarthrosis
 - Brachial plexus traction injury

Manipulation Under Anesthesia 64

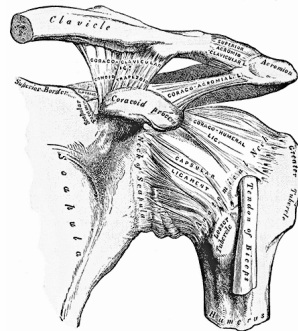
- Loew M. et al. *JSES* 2005
 - **30 patients following MUA**
 - Intra-articular damage following procedure
 - Hemarthrosis in all 30 patients
 - Synovitis in area of rotator interval in 22 patients
 - Superior capsule rupture in 11 patients
 - Anterior capsule rupture in 24 patients
 - Posterior capsule lesions in 16 patients
 - SLAP lesions in 4 patients
 - Subscapularis tear in 3 patients
 - Anterior labral detachment in 4 patients
 - MGHL torn in 2 patients

Manipulation Under Anesthesia **NOT** a benign procedure

Mobilization Under Anesthesia

65

- Roubal et al. *JOSPT*. 1996
 - 8 subjects received interscalene brachial plexus block followed by inferior and posterior glide manipulation
 - Gains with all motions
 - Flexion ↑ by 68°
 - Abduction ↑ by 77°
 - ER ↑ by 49°
 - IR ↑ by 45°



Manipulation Under Anesthesia

66

CLINICAL PRACTICE GUIDELINES

MARTIN J. KELLEY, DPT • MICHAEL A. SHAFFER, MSPT • JOHN E. KUHN, MD • LORI A. MICHENER, PT, PhD
AMEE L. SEITZ, PT, PhD • TIMOTHY L. UHL, PT, PhD • JOSEPH J. GODGES, DPT, MA • PHILIP W. MCCLURE, PT, PhD

Shoulder Pain and Mobility Deficits: Adhesive Capsulitis

INTERVENTION – TRANSLATIONAL MANIPULATION: Clinicians may utilize translational manipulation under anesthesia directed to the glenohumeral joint in patients with adhesive capsulitis who are not responding to conservative interventions. (Recommendation based on weak evidence.)

Treatment

67

- Kelley MJ et al. *JOSPT* 2009

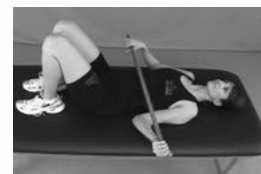TABLE 4	TREATMENT STRATEGIES BASED ON IRRITABILITY LEVEL		
	High irritability	Moderate irritability	Low irritability
Modalities	Heat/electrical stimulation	Heat/electrical stimulation	—
Activity modification	Yes	Yes	—
ROM/stretch	Short duration (1-5 s), pain-free, passive AAROM	Short duration (5-15 s), passive, AAROM to AROM	End range/overpressure, increased duration, cyclic loading
Manual techniques	Low-grade mobilization	Low- to high-grade mobilization	High-grade mobilization/sustained hold
Strengthen	—	—	Low- to high resistance and ranges
Functional activities	—	Basic	High demand
Patient education	+	+	+
Other	Intra-articular steroid injection	—	—

Abbreviations: AAROM, active assisted range of motion; AROM, active range of motion.

Treatment

68

- Stage I: Pre-Adhesive Stage
 - Synovial inflammation
 - Minimal or no loss of mobility
 - Interventions:
 - Maintain mobility
 - Early & frequent light motion exercises
 - Mid-Range submaximal isometrics



Treatment

69

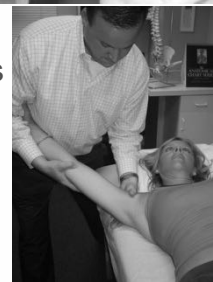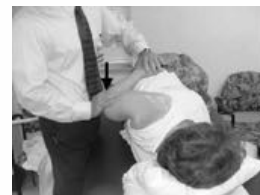- Stage II: Acute adhesive Stage/Freezing Stage
 - **Synovitis & Early adhesions**
 - **Interventions:**
 - Patient Education: Should not be aggressive
 - Explain pathophysiology
 - Consider injection
 - Pendulum exercises
 - AAROM
 - Sustained light stretches
 - Grade I-II mobilizations & distraction
 - Mid-range submaximal isometrics for RC and scapular musculature (****With Caution****)
 - HEP is critical: frequent short bouts of exercise



Treatment

70

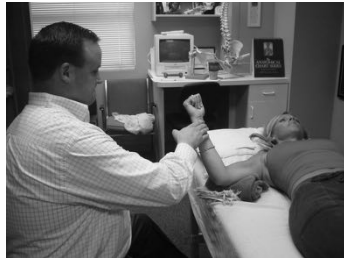- Stage III: Maturation / Fibrotic Stage / Frozen Stage
 - **Loss of axillary fold**
 - **Decreased synovitis**
 - **Interventions:**
 - Active warm-up
 - AAROM exercises
 - Inferior capsule stretches
 - Low load long duration (LLLD) stretches
 - Rotator cuff interval
 - Moist heat (Lentell: *JOSPT* 1992)
 - Grade III-IV mobilizations (single-plane)
 - End-range submaximal isometrics



Treatment

71

- Stage IV: Chronic Adhesive Stage / Thawing Phase
 - **Mature adhesions and motion restriction**
 - **Capsular end feel**
 - **Interventions:**
 - Active warm-up
 - Prolonged LLLD stretches (Moist heat)
 - Aggressive grade IV joint mobilizations (multi-plane)
 - Strengthening in new ROM



Surgical Management

72

- Arthroscopic Capsular Release
 - **Minimum 6 months conservative treatment**
 - **Berghs BM, et al. JSES. 2004**
 - Released RC interval and coracohumeral ligament
 - 25 patients had good results (mean f/u 14.8 mo)
 - **Additional portions of CLC released**
 - SGHL, MGHL, IGHL
 - Posterior capsule
 - **Post-Op Management**
 - CPM (Ide J, & Takagi K. JSES. 2004)
 - Daily PT (Watson L. et al. JSES. 2000)

Outcome Predictors

73

- Rill BK. et al. *AJSM* 2011
 - **Shorter duration of symptoms predicted a higher final American Shoulder and Elbow Surgeons Score (ASES) score**
 - **Following Non-Op treatment**
 - Patients with diabetes had lower final SST
 - **Ultimate surgical intervention**
 - Younger patients
 - Lower initial SST
 - **Multimodal non-operative treatment program is effective in most patients with adhesive capsulitis**
 - **Patients who do not improve, including those with diabetes, respond well to manipulation and arthroscopic release**

74

Patient Case: Adhesive Capsulitis

Case 1

75

- 53 yo woman with insidious onset of right shoulder pain in April 2016.
- No change in symptoms with physical therapy
 - **Primarily strengthening per patient**
- No change in symptoms s/p subacromial cortisone injection
- Referred for second opinion August 2016

Case 1

76

- Subjective report:
 - **C/O constant pain right shoulder as well as intermittent right upper arm pain**
 - **Current: 7/10, Best: 7/10, Worst: 10/10**
 - **Intensifiers**
 - Raising arm overhead
 - Wakes at night with pain
 - **Nullifiers**
 - Diminishes at rest but never without pain

Case 1

77

- History
 - **PMH is non-contributory**
 - **Sedentary occupation**
 - **Pt reports pain is significantly impacting quality of life**
 - **Goals: “To have normal use of right arm”**

Case 1

78

- Tests & Measures
 - **Posture:**
 - FHP, Forward shoulders, Increased thoracic kyphosis, Maintains right UE in guarded position
 - **PROM:**
 - Supine scaption: 100° with marked pain & guarding
 - Supine ER @ 30° Abduction: 20° with marked pain and guarding
 - Supine IR @ 30° Abduction: 45° with marked pain and guarding

Case 1

79

- Tests & Measures
 - **Palpation**
 - Marked pain along right GH and AC joint lines
 - **Joint Mobility**
 - Unable to assess due to pain
 - **Muscle Length**
 - Unable to assess due to pain
 - **Muscle Performance**
 - Unable to assess due to pain
 - **Special Tests**
 - Unable to assess due to pain

Case 1

80

- Outcome Measurement
 - **DASH**
 - 63% Disability Overall
 - 44% Disability on work module
- MRI
 - **IMPRESSION:** Bursal surface fraying and tearing of the supraspinatus tendon associated with tendinopathy and edema at the myotendinous junction. Mild tendinopathy in the infraspinatus and subscapularis tendons.

Case 1

81

- Clinical Impression
 - **Pt is a 53 yo female with signs and symptoms consistent with right adhesive capsulitis that is further complicated by fear avoidance behavior**

Case 1

82

- What are your thoughts on reactivity?
 - **Mild / Moderate / Marked**
- What are your thoughts on stage of adhesive capsulitis?
 - **Pre-Adhesive**
 - **Acute Adhesive / Freezing Stage**
 - **Maturation / Fibrotic / Frozen Stage**
 - **Chronic Adhesive / Thawing Stage**

Case 1

83

- What would you do for treatment?

(Put your answer in the Q&A)

[Answers are anonymous]

Case 1

84

- Treatment Progression
 - **Intra-articular cortisone injection under fluoroscopic guidance on 8/10/16**
 - Significant reduction in pain to 0/10 at rest and 3/10 with activity
 - **Postural re-education**
 - **Progressive ROM activity including mobilization**
 - **Strength in new ROM**

Case 1

85

- Outcome
 - Discharged to HEP in 11/2015
 - Full A-PROM in all planes
 - Gross strength RC and Scapular musculature 4+/5
 - DASH: 10% Disability

Thank You

86

Remember:

It is a marathon..... not
a sprint